

## PRACTICE GUIDANCE

# A multidisciplinary approach to the diagnosis and management of Wilson disease: 2022 Practice Guidance on Wilson disease from the American Association for the Study of Liver Diseases

Michael L. Schilsky<sup>1</sup> | Eve A. Roberts<sup>2</sup> | Jeff M. Bronstein<sup>3</sup> | Anil Dhawan<sup>4</sup> |  
 James P. Hamilton<sup>5</sup> | Anne Marie Rivard<sup>6</sup> | Mary Kay Washington<sup>7</sup> |  
 Karl Heinz Weiss<sup>8</sup> | Paula C. Zimbrea<sup>9</sup>

<sup>1</sup>Medicine and Surgery, Yale University School of Medicine, New Haven, Connecticut, USA

<sup>2</sup>Paediatrics, Medicine, Pharmacology and Toxicology, University of Toronto, Toronto, Ontario, Canada

<sup>3</sup>Neurology, University of California Los Angeles, Los Angeles, California, USA

<sup>4</sup>Paediatric Liver, GI and Nutrition Centre and MowatLabs, King's College Hospital, London, UK

<sup>5</sup>Medicine, Johns Hopkins University School of Medicine, Baltimore, Maryland, USA

<sup>6</sup>Food and Nutrition Services, Yale New Haven Hospital, New Haven, Connecticut, USA

<sup>7</sup>Pathology, Immunology and Microbiology, Vanderbilt University Medical Center, Nashville, Tennessee, USA

<sup>8</sup>Internal Medicine, Salem Medical Center, Heidelberg, Germany

<sup>9</sup>Psychiatry, Yale University School of Medicine, New Haven, Connecticut, USA

## Correspondence

Michael L. Schilsky, Yale University School of Medicine, 333 Cedar Street, LMP 1080, PO Box 208019, New Haven, CT 06520-8019, USA.

Email: [michael.schilsky@yale.edu](mailto:michael.schilsky@yale.edu)

**Abbreviations:** AASLD, American Association for the Study of Liver Diseases; AI, adequate intake; AIH, autoimmune hepatitis; ALF, acute liver failure; ALI, acute liver injury; ALT, alanine aminotransferase; AST, aspartate aminotransferase; *ATP7B*, ATPase copper transporting beta (gene); ATPase, adenosine triphosphatase; CCA, cholangiocarcinoma; CDG, congenital disorder of glycosylation; CNS, central nervous system; CuEXC, exchangeable copper; ECT, electroconvulsive therapy; FDA, Food and Drug Administration; HCC, hepatocellular carcinoma; INR, international normalized ratio; KF, Kayser–Fleischer; MDD, major depressive disorder; MDR3, multidrug-resistance protein 3; MEDNIK, intellectual (Mental) disability, enteropathy, deafness, neuropathy, ichthyosis, keratoderma; MELD, Model of End-stage Liver Disease; MRI, magnetic resonance imaging; NCC, non-ceruloplasmin-bound copper; NWI, New Wilson Index; PGM1, phosphoglucomutase 1; RD, registered dietitian; RDA, recommended dietary allowance; TTM, tetrathiomolybdate; UWDRS, Unified Wilson's Disease Rating Scale; WD, Wilson disease.

Michael L. Schilsky and Eve A. Roberts are co-first authors.

This is the complete version of the American Association for the Study of Liver Diseases (AASLD) 2022 Guidance on Wilson disease (WD). It provides a contemporary approach to diagnosis and management of WD. Guidance documents, developed by a panel of experts, are formulated as recommendations to help clinicians implement the most current strategies for diagnosis and management. This Guidance was developed with the support and oversight of the AASLD Practice Guidelines Committee. The AASLD Practice Guidelines Committee chose to commission a guidance, rather than a guideline, because of the paucity of randomized controlled trials on this topic. AASLD Guidelines are supported by systematic reviews of the literature, formal ratings of evidence quality and strength of recommendations, and, if appropriate, meta-analysis of results using the Grading of Recommendations Assessment Development and Evaluation system. In contrast, this narrative review and its guidance statements are based on (1) formal review and analysis of the recently published international literature on WD, (2) guideline policies of the AASLD, and (3) the authors' experience.

This practice Guidance is intended for use by physicians and other health professionals. As clinically appropriate, guidance statements should be tailored to the needs of individual patients. Specific guidance statements are evidence based whenever possible. Where such evidence is unavailable or inconsistent, guidance statements are based on expert consensus opinion. An executive summary providing a convenient overview is available (<https://doi.org/10.1002/hep.32805>); however, the version herewith, along with its supplementary materials, is the definitive document for this Guidance.

Supplemental Digital Content is available for this article. Direct URL citations appear in the printed text and are provided in the HTML and PDF versions of this article on the journal's website, [www.hepjournal.com](http://www.hepjournal.com).

Copyright © 2023 American Association for the Study of Liver Diseases.

## INTRODUCTION

Copper is an essential metal required as a cofactor for many metalloproteins. Although the average diet contains 2–5 mg/day of copper, the recommended intake is 0.9 mg/day. Ingested copper is absorbed by enterocytes mainly in the duodenum and proximal small intestine. Absorbed copper is transported in the portal circulation in association with albumin and the amino acid histidine and is avidly removed from the circulation by the liver. Hepatocytes utilize copper for metabolic needs, incorporate copper into nascent ceruloplasmin, and transport excess copper into bile. Most excess copper is excreted via this biliary pathway into feces; only a minor amount is excreted via the kidneys. Impaired biliary copper excretion can lead to hepatic copper retention.

Wilson disease (WD; hepatolenticular degeneration) was first comprehensively described in 1912 by Kinnier Wilson as “progressive lenticular degeneration,” a familial, lethal neurological disease accompanied by cirrhosis.<sup>[1]</sup> Subsequently, the role of copper in its pathogenesis was established and the autosomal recessive pattern of inheritance determined.<sup>[2,3]</sup> Following localization of the gene associated with WD on chromosome 13,<sup>[4]</sup> it was identified as encoding a metal-transporting P-type adenosine triphosphatase (ATPase).<sup>[5–7]</sup> This gene, ATPase copper transporting beta (*ATP7B*), is expressed mainly in hepatocytes. The gene product ATP7B facilitates transmembrane transport of copper within hepatocytes. Absent or impaired ATP7B function decreases biliary excretion of copper, resulting in toxic hepatocellular copper accumulation. Eventually exceeding storage capacity, hepatic copper released into the bloodstream deposits in other organs, notably the brain, kidneys, and cornea. Loss of functional ATP7B diminishes hepatocellular biosynthetic incorporation of copper into ceruloplasmin. This explains the decreased blood level of ceruloplasmin in most patients with WD because apoceruloplasmin has a shorter circulating half-life than ceruloplasmin.<sup>[8]</sup>

WD occurs worldwide. Its prevalence was estimated at approximately 30 per million population<sup>[9,10]</sup>; however, newer data suggest higher prevalence.<sup>[11–14]</sup> WD can present clinically as liver disease, a progressive neurological disorder (hepatic dysfunction being less apparent or occasionally absent), a psychiatric illness, or as a combination of these. WD presents with isolated liver disease more often in children and younger adult patients than in older adults. Symptoms at any age are frequently nonspecific.

## CLINICAL SPECTRUM OF DISEASE

Most pediatric patients (less than 18 years-old) with WD present with hepatic disease, whereas adults present

with hepatic disease with or without concurrent neuropsychiatric disease. The broad spectrum of liver disease (Table 1) necessitates heightened clinical suspicion for the diagnosis.<sup>[15]</sup> Screening first-degree relatives of patients with WD may identify affected individuals without clinical symptoms. They are best described as “asymptomatic.” However, some organ damage due to copper accumulation may already be present in the liver and other organs of asymptomatic patients. Untreated, asymptomatic patients with evidence of organ damage typically progress to symptomatic WD. Thus, their timely identification is critically important. Some asymptomatic affected individuals may recognize subtle symptoms of WD on detailed review of systems.

The age of presentation for symptomatic WD is both younger and older than generally appreciated. It is mainly, but not exclusively, 3–55 years-old. WD is increasingly diagnosed in children who are less than 5 years-old. Clinical findings may be nonspecific in children who are less than 2 years-old.<sup>[16–22]</sup> More severe liver disease, including cirrhosis in a 3-year-old<sup>[23]</sup> and acute liver failure (ALF) in a 5-year-old,<sup>[24]</sup> was infrequently reported. WD was also confirmed by molecular

**TABLE 1** Clinical patterns of disease in Wilson disease

Hepatic	<ul style="list-style-type: none"> <li>• Asymptomatic hepatomegaly</li> <li>• Isolated splenomegaly</li> <li>• Persistently elevated serum aminotransferase activity (AST, ALT)</li> <li>• Fatty liver</li> <li>• Acute hepatitis, varying severity including acute liver injury (ALI)</li> <li>• Resembling autoimmune hepatitis</li> <li>• Cirrhosis—compensated or decompensated</li> <li>• Acute liver failure</li> </ul>
Neurological	<ul style="list-style-type: none"> <li>• Dysarthria</li> <li>• Movement disorders (tremor, involuntary movements)</li> <li>• Pseudobulbar palsy</li> <li>• Drooling, transfer dysphagia</li> <li>• Rigid dystonia</li> <li>• Dysautonomia</li> <li>• Seizures</li> <li>• Sleep disorders, insomnia</li> </ul>
Psychiatric	<ul style="list-style-type: none"> <li>• Depression</li> <li>• Bipolar disorder/bipolar spectrum</li> <li>• Neurotic behaviors</li> <li>• Personality changes</li> <li>• Psychosis</li> </ul>
Other systems	<ul style="list-style-type: none"> <li>• Eye: Kayser–Fleischer rings, sunflower cataracts</li> <li>• Renal abnormalities: aminoaciduria and nephrolithiasis</li> <li>• Skeletal abnormalities: premature osteoporosis and arthritis</li> <li>• Cardiomyopathy, dysrhythmias</li> <li>• Pancreatitis</li> <li>• Hypoparathyroidism</li> <li>• Infertility, repeated miscarriages</li> </ul>

Abbreviations: ALI, acute liver injury; ALT, alanine aminotransferase; AST, aspartate aminotransferase.

genetic studies in patients in their early 70s<sup>[25,26]</sup> and 80s.<sup>[27]</sup> In older individuals displaying concurrent neurological or psychiatric symptoms and biochemical or histological findings suggesting WD, further evaluation is warranted. Age alone does not contravene a diagnosis of WD.

## Hepatic WD

Liver disease associated with WD can be highly variable (Table 1), ranging from asymptomatic biochemical abnormalities to ALF. Children may be entirely asymptomatic, with hepatomegaly or abnormal serum aminotransferases found incidentally. Some patients have a brief clinical illness resembling an acute viral hepatitis; others present with features indistinguishable from autoimmune hepatitis (AIH); yet others have steatosis on liver biopsy or imaging. At presentation, many have signs of chronic liver disease, such as chronic hepatitis, or evidence of cirrhosis, either compensated or decompensated. Isolated splenomegaly due to clinically inapparent cirrhosis with portal hypertension has been noted. ALF due to WD, accounting for approximately 3% of all ALF, is typically associated with nonimmune (Coombs-negative) intravascular hemolysis, coagulopathy, progressive encephalopathy, and renal dysfunction. Some patients have transient episodes of jaundice due to hemolysis, without apparent liver failure or clinically evident liver disease.

Pediatric patients with apparent AIH and adults with presumed AIH not readily responding to therapy should be assessed for WD because elevated serum immunoglobulins and detectable nonspecific autoantibodies are found in both conditions.<sup>[28,29]</sup> Pediatric and adolescent patients with hepatic steatosis should be assessed for WD, particularly if their body mass index and waist circumference are normal by pediatric standards.

## Neurologic WD

Neurological manifestations of WD are also extremely variable, mainly reflecting damage to the central nervous system (CNS). Symptoms including involuntary movements, tremor, dystonic smile, and dysarthria are due to extrapyramidal involvement, but involvement of the pyramidal tract and cerebellum also occurs. Most with neurologic WD also have underlying hepatic disease, though not all have cirrhosis.<sup>[30]</sup> There is no clear correlation between specific *ATP7B* mutations and risk of neurological presentation.<sup>[31]</sup>

Neurological symptoms of WD include dysarthria, dystonia, gait abnormalities, ataxia, tremor, parkinsonism, and chorea; seizures occur rarely. Many patients have more than one neurological manifestation concurrently; neurological features can change over time. The

frequencies of these signs have not been systematically evaluated using one set of criteria. A summary of several independent case series (Table 2) indicates that the most common neurological symptom at presentation is dysarthria.<sup>[32–35]</sup> Gait abnormalities (including ataxia), dystonia, tremor, and parkinsonism are also very common (Table 2). Depression, anxiety, and mild cognitive difficulties very frequently precede overt neurological problems.<sup>[1]</sup> Dystonia in WD can be focal, segmental, or generalized; the focal dystonia of facial expression causing involuntary smiling (risus sardonicus) is fairly common.<sup>[36]</sup> Tremor can also be present at rest, with posture, or with action. The well-described rubral wing-beating tremor occurs infrequently. Sensory symptoms and weakness representing peripheral neuropathy are very unusual as the presentation of WD.<sup>[37]</sup>

Comprehensive clinical assessment is essential. A complete neurological examination should be performed by a neurologist or movement disorder specialist in all patients with WD with neurological signs or symptoms detected on examination by any healthcare provider. In those with abnormal neurological findings, serial examination helps determine progression or recovery. Imaging modalities such as magnetic resonance imaging (MRI) are of limited value in determining the extent of clinical neurological disease but may help initially in supporting a diagnosis of WD and excluding other neurological disorders. Evaluation of the extrapyramidal system should include observation for posturing of the extremities or torso (i.e., dystonia), irregular dance-like movements (chorea), determination of tone (parkinsonism and dystonia), and evidence of tremor at rest, with posture or action, or as a rubral wing-beating

**TABLE 2** Summary of neurological symptoms at presentation of Wilson disease based on four independent case series<sup>[31,37,280,419]</sup>

Neurological manifestations at onset	% of patients	Treatments
Dysarthria	46–97	Speech therapy
Gait abnormality/ ataxia/cerebellar	28–75	Physical therapy, assistive device
Dystonia	38–69	Trihexyphenidyl, botulinum toxin (for focal symptoms), clonazepam
Parkinsonism	12–58	Carbidopa/levodopa, dopamine agonist
Postural tremor	55	Primidone, propranolol, clonazepam
Dysphagia	50	Swallow therapy, thickeners
Chorea/athetosis	6–30	Neuroleptics, VMAT2 inhibitors
Seizures	6–28	Anticonvulsants
Rest tremor	4	Carbidopa/levodopa, dopamine agonist

Abbreviation: VMAT2, vesicular monoamine transporter-2.

tremor. The pyramidal system is primarily evaluated by checking reflexes and tone (hyperreflexia and spasticity). Cerebellar function is typically evaluated by having the patient perform finger to nose and heel/knee/shin testing. Gait should be evaluated for speed and fluidity: widened stance may be evident with cerebellar involvement. Cognitive evaluation utilizing the Montreal Cognitive Assessment (MoCA)<sup>[38]</sup> or Folstein Mini Mental Status Examination (MMSE) could be repeated every 3–6 months, when abnormal at the outset, to monitor changes with treatment. In those with possible altered cognition, a comprehensive neuropsychiatric evaluation can be obtained at baseline and followed over time.

Specialized neurological rating scales such as the Unified Wilson's Disease Rating Scale (UWDRS)<sup>[39]</sup> and the Global Assessment for Wilson's Disease<sup>[40]</sup> were developed for research purposes. These rating scales, or selected portions of them, help in evaluating quantitatively disease progression and response to therapy. Elements of the UWDRS focused on the patient's symptoms along with the MoCA and/or MMSE may help with monitoring changes in cognition objectively.

## Psychiatric manifestations of WD

Psychiatric symptoms are wide-ranging. They can occur initially or develop despite WD treatment. Importantly, psychiatric disease may be intrinsic to or independent of WD. Psychiatric features of WD are more common than generally acknowledged. Approximately two thirds of patients had psychiatric symptoms at the beginning of their illness, with or without hepatic or neurological findings<sup>[41,42]</sup>; approximately 71% also experienced neuropsychological symptoms over time.<sup>[42]</sup> Presence of more than one psychiatric condition is common: a cross-sectional study of 50 patients using Structured Clinical Interview for DSM Disorders found that 40% met criteria for at least three psychiatric diagnoses.<sup>[42]</sup>

The purely psychiatric presentation frequently results in delayed diagnosis. The average time between the onset of psychiatric symptoms and WD diagnosis was 2.4 years.<sup>[43]</sup> Up to 20% of patients with WD had seen a psychiatrist prior to their WD diagnosis.<sup>[44]</sup> In adults, the most common conditions include mood disorders (depressive or bipolar spectrum), psychotic disorders, sleep disturbances, and subtle cognitive dysfunction.

### Depressive disorders

The most common type of depression in WD is major depressive disorder (MDD), an episodic illness recurrent in many cases.<sup>[43]</sup> The prevalence of depression in patients with WD varies broadly (4%–47%) depending on the assessment instrument.<sup>[45,46]</sup> The mechanisms of

depression in WD appear similar to those in MDD, namely, alteration of serotonergic transmission in the thalamus–hypothalamus and midbrain–pons region, notably with low density of the presynaptic serotonin transporter.<sup>[47]</sup> In contrast, dysthymic disorder (dysthymia) is a chronic depressive disorder of at least 2 years' duration in adults, differing slightly from MDD clinically. Patients with WD may have dysthymic disorder<sup>[45]</sup>; its distinction from MDD has treatment implications.

### Bipolar disorders/bipolar spectrum

Bipolar presentations in WD range from a full manic episode to mild mood instability or impulsivity. Prevalence of bipolar disorder in patients with WD is approximately 18%–39%.<sup>[43]</sup> Features of a full manic episode include abnormally and persistently elevated, expansive, or irritable mood; persistently increased goal-directed activity or energy; inflated self-esteem or grandiosity; decreased need for sleep; being more talkative or wanting to keep talking; flight of ideas or subjective racing thoughts; distractibility; and prolonged (at least 1 week) increase in goal-directed but risky activities. Bipolar disorder in WD significantly impacts quality of life.<sup>[48]</sup> Patients with WD may present with various degrees of mood instability that do not meet criteria for mania or hypomania but nevertheless impair quality of life.<sup>[46,49]</sup>

### Psychotic disorders

Psychosis in WD includes frank delusions and/or thought disorder or disorganized thinking.<sup>[44,50–54]</sup> Cases were reported where patients carried the diagnosis of schizophrenia for years prior to their WD diagnosis.

### Sleep disturbances

Severe sleep disturbances, which can rarely be a presentation of WD, are a long-term issue. Overall, patients with WD had a lower sleep quality,<sup>[55]</sup> with frequent nocturnal awakening, occasional sleep paralysis or catalepsy,<sup>[56]</sup> and worse daytime somnolence than controls.<sup>[57,58]</sup> Rapid eye movement sleep behavior disorder (RBD) was reported, associated with more nightmares and violent dreams than in patients without RBD.<sup>[59]</sup> Sleep disturbance disorders in WD require definitive diagnosis for selecting appropriate treatment.

### Cognitive problems

Historically, late stages of untreated WD were said to be associated with subcortical dementia. Experience



with current WD treatments has shown that the disease does not automatically lead to major cognitive decline.<sup>[60–62]</sup> Cognitive problems include deficits in executive functioning, abstract thinking, working memory, reasoned control of impulsive behaviors, and attention deficits. Cognitive problems are more pronounced with neurologic or hepatic WD; in the latter, hepatic encephalopathy may contribute to dysfunction. Importantly, in many cases, cognitive deficits may be revealed only by formal testing in asymptomatic patients with WD.<sup>[63,64]</sup> With respect to decision-making, patients with WD were more likely to prefer disadvantageous choices, unlike healthy controls.<sup>[65]</sup> These subtle cognitive deficits may influence adherence to treatment.

## Personality and behavioral changes

WD may present at any time with behavioral changes not meeting criteria for a specific psychiatric disease: irritability,<sup>[42,66]</sup> impaired social judgment or disinhibition,<sup>[42,49]</sup> apathy,<sup>[42]</sup> “belligerence,”<sup>[49]</sup> or “incongruent behavior.”<sup>[66]</sup> Personality changes are described in up to 57% of patients with WD.<sup>[41,66]</sup> Children and adolescents may present with nonspecific behavioral disturbances or decline in academic performance.

## Diagnostic challenges

A major challenge is to distinguish a psychiatric disorder intrinsic to WD from psychiatric disorders in reaction to having WD. Essential for the diagnosis of depressive illness due to a medical condition is the existence of a temporal association between the onset, exacerbation, or remission of the general medical condition and the mood disturbance. For WD, depression may be an early symptom before the disease has caused disability, financial burden, or relationship problems. In this instance, the diagnosis of adjustment disorder does not apply. It is critical to establish the timeline of symptoms (hepatic, neurologic, psychiatric) in the clinical presentation.

Another impediment to diagnosing WD is the tendency to attribute behavioral changes to more prevalent behavioral disorders. Irritability or moodiness may be attributed to “typical adolescent behavior” or to attention deficit hyperactivity disorder. The problem of concurrent psychiatric disorders is challenging: it may be difficult to discern whether the psychiatric disorder is independent of WD or its feature. In this situation, patients need highly individualized diagnosis and management of their psychiatric disorder by an experienced specialist.

Given the high prevalence of psychiatric comorbidities in WD, early assessment is advisable. It is

reasonable to utilize screening instruments for these disorders in routine practice and then arrange formal consultation when screening or symptoms suggest a psychiatric component to a patient's WD.

## Ophthalmological features of WD

Kayser–Fleischer (KF) rings represent copper deposited in Descemet's membrane of the cornea. When visible by direct inspection, they appear as golden-brownish pigment near the limbus. A slit-lamp examination, sometimes aided by gonioscopy, by an experienced observer is required to identify KF rings. KF rings are not entirely specific for WD because they may rarely be found with chronic cholestatic diseases<sup>[67–69]</sup> and neonatal cholestasis<sup>[70]</sup>; however, these disorders can usually be easily distinguished from WD. Large series of patients with WD show that KF rings are present in only 44%–62% of patients with mainly hepatic disease at the time of diagnosis.<sup>[15,71–74]</sup> In children presenting with liver disease, KF rings are usually absent.<sup>[75–77]</sup> Although almost invariably present in patients with neurologic WD at presentation, KF rings may be absent in a few.<sup>[78]</sup> Anterior segment optical coherence tomography is a new technology for assessing KF rings both qualitatively and quantitatively, specifically determining their size and location within the cornea.<sup>[79–83]</sup> Other new technologies for imaging KF rings include Scheimpflug imaging<sup>[84]</sup> and in vivo confocal microscopy.<sup>[85]</sup>

Other ophthalmological changes in WD include sunflower cataracts, also found by slit-lamp examination, which are deposits of copper in the lens.<sup>[86,87]</sup> These typically do not obstruct vision. Both KF rings and sunflower cataracts will gradually disappear with effective medical treatment or following liver transplantation. KF rings first appear at the superior and inferior aspects of the limbus and then become circumferential; they disappear in the reverse sequence.

Evidence of damage to small unmyelinated nerves in the corneal subbasal nerve plexus has been found by corneal confocal microscopy and attributed to copper excess.<sup>[88]</sup> These findings may have diagnostic importance.

## Hematologic manifestations of WD

Hematological features of untreated WD typically involve hemolysis. Severe nonimmune intravascular hemolysis is an important feature of classic presentation of ALF due to WD. It results in a sudden severe drop in hemoglobin. Hemolysis is due to the copper-associated damage to erythrocyte membranes,

evident as a reduction in red blood cell count and hemoglobin level, and unconjugated hyperbilirubinemia. Hemolysis may also occur transiently in WD presenting as chronic disease. Hemolysis was a presenting feature in 25 of 220 cases (12%).<sup>[89]</sup> Patients with WD and a history of transient jaundice may have had hemolysis independent of liver disease.

Thrombocytopenia and leukopenia occur regularly with hypersplenism, which may be a presenting or later feature of hepatic WD.

## Other organ involvement in WD

Important extrahepatic manifestations apart from neurological or psychiatric disease may be present at time of diagnosis of WD.<sup>[90]</sup> Most are direct or indirect effects of copper accumulation and toxicity. Cardiac and bony abnormalities may be present initially or become evident later.

Renal abnormalities have been characterized as a Fanconi syndrome (aminoaciduria, phosphaturia, microscopic hematuria, and defective urinary acidification).<sup>[91]</sup> Recurrent muscle weakness due to hypokalemia, associated with an incomplete proximal renal tubular acidosis, was reported as a presenting feature of WD.<sup>[92]</sup> Hypouricemia occurs, likely due to excess urinary loss of urate, possibly contributing to development of nephrolithiasis. Nephrolithiasis may also be a presenting feature of WD.<sup>[93–95]</sup> Whether any of these abnormalities are due to abnormal renal tubular expression or function of ATP7B is uncertain.

Some patients, notably in the Indo-Pakistani subcontinent, have prominent skeletal abnormalities at presentation. Skeletal changes resemble rickets and may include demineralization; associated renal abnormalities indicate renal tubular dysfunction; muscle weakness may also be present. This so-called “osseomuscular” WD is uncommon but distinctive. Whether patients with WD are at increased risk for premature osteoporosis and arthritis<sup>[96]</sup> over the course of treatment is unclear.<sup>[97,98]</sup> A recent meta-analysis showed a trend toward increased risk of osteopenia and osteoporosis in WD, but the study was limited by paucity of pertinent clinical research studies available.<sup>[99]</sup>

Cardiac problems associated with WD include cardiomyopathy<sup>[100,101]</sup> and arrhythmias. Atrial fibrillation<sup>[102]</sup> was found more commonly in patients with WD than in the general population. Left ventricular hypertrophy may also be found.<sup>[103]</sup> Cardiac abnormalities can present in childhood<sup>[104]</sup>; they can develop independent of treatment for WD. Dysautonomia has been described, and some patients may have inappropriate cardiovascular responses to positional changes or have dysrhythmia.<sup>[105–107]</sup>

Endocrine abnormalities in patients with WD include hypoparathyroidism<sup>[108]</sup> and infertility or repeated miscarriages,<sup>[109–112]</sup> which may be independent of severity of hepatic disease. Pancreatitis at clinical presentation was attributed to copper deposition in the pancreas.<sup>[113]</sup>

### Guidance statements 1–5

1. WD should be considered in any individual with liver abnormalities of uncertain cause. Age alone should not be the basis for eliminating a diagnosis of WD.
2. WD must be excluded in any patient with unexplained liver disease associated with neurological or psychiatric disorder. Assessment by a neurologist specializing in movement disorders may be advantageous. Psychiatric evaluation is essential for any patient with WD presenting with psychiatric or neuropsychiatric features of WD.
3. WD should be suspected in any patient presenting with ALF with nonimmune hemolytic anemia including acute intravascular hemolysis. These patients require urgent evaluation for liver transplantation.
4. Evaluation for WD is critical in patients exhibiting recurrent self-limited nonimmune hemolysis.
5. At clinical presentation, WD may involve organ systems besides the liver and nervous system (such as renal, musculoskeletal, cardiac, or endocrine).

## DIAGNOSTIC TESTING

Since Wilson's initial description, diagnostic advances have enabled evaluation for WD in individuals in whom WD is suspected prior to development of neurological symptoms. These include recognition of KF rings,<sup>[114]</sup> identification of low serum ceruloplasmin concentration in most patients,<sup>[115]</sup> and measurement of copper concentration in percutaneous liver biopsy specimens. The new development is genotype analysis by direct examination for disease-specific *ATP7B* mutations, including by whole-exome/genome sequencing.

Patients with cirrhosis, neurological manifestations, and KF rings are easily diagnosed as having WD: they resemble the original clinical description. Patients presenting with liver disease who were 5–40 years-old and had low serum ceruloplasmin and KF rings were regarded as having textbook WD.<sup>[116]</sup> However, approximately 50% of patients presenting with liver disease lack two of these criteria and pose a diagnostic

challenge.<sup>[15]</sup> Increasingly, patients come to medical attention when their clinical disease is mild. A scoring system has been devised to aid diagnosis, based on a composite of key parameters.<sup>[117]</sup>

Though availability of genetic testing for *ATP7B* mutations has improved, this testing is relatively expensive and not universally available. In addition, patients in whom the genetic testing is inconclusive require further clinical and biochemical testing to diagnose WD. A molecular genetic strategy using direct mutation analysis may be particularly effective in identifying affected siblings of probands with two identified *ATP7B* mutations.

Biochemical liver tests

Serum aminotransferase activities are generally abnormal in WD except at a very early age (infancy). The degree of elevation of aminotransferase activity may be relatively mild, disproportionate to the severity of the liver disease. For those with cirrhosis, aspartate aminotransferase (AST) is often elevated at levels above alanine aminotransferase (ALT).

Transient hyperbilirubinemia, mainly unconjugated, may occur with brief self-limited episodes of hemolysis.<sup>[118]</sup> Low-normal or subnormal serum alkaline phosphatase is typical of ALF due to WD<sup>[119]</sup> associated with intravascular hemolysis; it is also found with severe WD not meeting criteria for ALF (i.e., acute liver injury [ALI] without hepatic encephalopathy)<sup>[119,120]</sup> and may be associated with episodic hemolysis in WD.<sup>[121]</sup>

Ceruloplasmin

This 132-kDa glycoprotein is synthesized in hepatocytes as a metalloprotein containing six copper atoms per molecule of ceruloplasmin (holoceruloplasmin) and secreted into the circulation. A small proportion of the protein lacking copper (apoceruloplasmin) is also secreted but has a shorter circulating half-life. Copper within ceruloplasmin accounts for 90% of circulating copper in normal individuals and is not exchangeable under physiologic conditions. Ceruloplasmin is both a ferroxidase playing a role in iron mobilization and a nitric oxide oxidase, influencing nitric oxide homeostasis.<sup>[122]</sup> It acts as an oxidase for substrates such as *p*-phenylamine diamine<sup>[123]</sup> and *o*-dianisidine,<sup>[124]</sup> the basis for enzymatic assays for the protein. Levels of serum ceruloplasmin may be measured enzymatically by their copper-dependent oxidase activity toward these substrates or to iron<sup>[125]</sup> or immunologically by antibody-dependent assays. Results generally are regarded as equivalent,<sup>[126]</sup> but immunoassays may overestimate ceruloplasmin concentrations because they detect both apoceruloplasmin and holoceruloplasmin. Most clinical

laboratories use immunologic methods, and reference ranges vary. Consequently, new assays for direct determination of ceruloplasmin copper are being developed.<sup>[127]</sup> Serum ceruloplasmin is an acute-phase reactant, and concentrations are elevated by acute inflammation. Because the ceruloplasmin gene has estrogen response elements, serum ceruloplasmin is also elevated by hyperestrogenemia in pregnancy, estrogen supplementation, and use of some oral contraceptive pills.

Serum ceruloplasmin levels are physiologically very low in early infancy to the age of 6 months, peak at higher than adult levels in early childhood (at approximately 30–50 mg/dl), and then settle to the adult range. Serum ceruloplasmin is decreased in most patients with WD. Serum ceruloplasmin may be low in other conditions (Table 3), including absolute copper deficiency.<sup>[128–131]</sup> Serum ceruloplasmin within the normal range does not exclude the diagnosis of WD.

A serum ceruloplasmin level typically below the laboratory determined lower level of normal (usually approximately 20 mg/dl) has been considered consistent with WD, and diagnostic if associated with KF rings. Serum ceruloplasmin as a screening or diagnostic test has major limitations.<sup>[15,132]</sup> Several reports suggest that serum ceruloplasmin is particularly uninformative diagnostically in children.<sup>[71,77,133]</sup> Its diagnostic utility might have been greater from the mid-1950s onward, when the enzymatic assay predominated.<sup>[134–136]</sup> A recent

TABLE 3 Other disorders associated with low serum ceruloplasmin

Nonselective renal protein loss
Protein-losing enteropathy
Severe chronic liver disease with global hepatic synthetic deficit
Neurological disorders (cervical dystonia)
Absolute copper deficiency
Improper formulation of TPN omitting copper
After gastric or bariatric surgery
Chronic Ingestion of zinc in excess
Menkes disease
Aceruloplasminemia
MEDNIK syndrome ( <i>AP1S1</i> disorder)
<i>AP1B1</i> disorder
Congenital glycosylation disorder
PGM1-CDG
CCDC115-CGD
TMEM119-CDG
Niemann-Pick type C

Abbreviations: *AP1B1*, adaptor related protein complex 1 subunit beta 1 (gene); *AP1S1*, adaptor-related protein complex 1 subunit sigma 1 (gene); CCDC115, coiled-coil domain containing 115; CDG, congenital disorder of glycosylation; MEDNIK, intellectual (Mental) disability, enteropathy, deafness, neuropathy, ichthyosis, keratoderma; PGM1, phosphoglucomutase 1; TMEM119, transmembrane protein 119; TPN, total parenteral nutrition.

study in which patients with WD were identified and confirmed by molecular genetic testing pointed out that the sensitivity and specificity of testing using serum ceruloplasmin varied by the selected cutoff values.<sup>[137]</sup> Serum ceruloplasmin concentrations below 20, 14, and 10 mg/dl showed positive predictive values of 48.3%, 100%, and 100%, respectively, and negative predictive values of 98.7%, 97.1%, and 91.9%. In this study, a serum ceruloplasmin threshold of 14 mg/dl, measured immunologically, achieved 100% sensitivity and specificity in the validation group. Some simple heterozygotes have subnormal of serum ceruloplasmin<sup>[134]</sup>; however, in this study,<sup>[137]</sup> all simple heterozygotes with subnormal serum ceruloplasmin had values >14 mg/dl. In the Leipzig score,<sup>[117]</sup> the informative cutoff is 10 mg/dl; some regard serum ceruloplasmin <5 mg/dl as highly informative for the diagnosis of WD.

## Uric acid

Serum uric acid may be decreased at presentation with symptomatic hepatic or neurologic WD because of associated renal tubular dysfunction. Abnormal reabsorption of urate may occur.<sup>[138]</sup> Insufficient evidence is available to determine the predictive value of a low serum uric acid in WD.

## Serum copper and non-ceruloplasmin-bound copper

Total serum copper (90% of which is nonexchangeable copper within ceruloplasmin) in WD is usually below normal levels, decreased in proportion to the level of ceruloplasmin in the circulation. Normal or elevated serum copper levels in the face of decreased levels of ceruloplasmin, as occurs in patients with WD with liver injury, indicate an increased concentration of copper not bound to ceruloplasmin in the blood (non-ceruloplasmin-bound copper [NCC]), that is to say, copper that is exchangeable and thus bioavailable.

The serum NCC concentration has been proposed as a diagnostic test for WD but was never validated as such. NCC can be estimated from the serum copper and ceruloplasmin. Its limitations when thus calculated are significant. As the amount of copper associated with ceruloplasmin is approximately 3.15 µg of copper per milligram of ceruloplasmin, the NCC is the difference between the serum copper concentration in micrograms per deciliter and 3.15 times the serum ceruloplasmin concentration in milligrams per deciliter.<sup>[139–141]</sup> NCC is >25 µg/dl in most untreated patients (expected normal range 10–15 µg/dl). NCC may be elevated in ALI and liver failure of any etiology,<sup>[142,143]</sup> in chronic cholestasis,<sup>[144]</sup> and in copper intoxication from ingestion or poisoning. This limits the diagnostic utility of NCC for WD. However,

in ALF due to WD, serum copper is markedly elevated (usually >200 µg/dl) due to sudden massive hepatic necrosis with copper release from disrupted hepatocytes. This is typically much higher than in ALF due to other etiologies.<sup>[145]</sup> NCC is likewise elevated in ALF due to WD.

The problem with NCC is that the calculated NCC utilizing ceruloplasmin measured immunologically is inherently flawed as a diagnostic and monitoring test for WD.<sup>[146]</sup> Because the immunologic serum ceruloplasmin measurement overestimates holoceruloplasmin, estimated NCC may yield a zero or negative number and thus be uninterpretable. To circumvent the difficulty in accurately determining NCC based on immunologic assays of serum ceruloplasmin, alternative assays have been developed. Examination of the lower molecular weight fraction below 30-kDa cutoff obtained by centrifugal ultrafiltration was proposed as a more direct method for determining NCC.<sup>[147]</sup> In practice, this method suffers from difficulty in obtaining accurate values for “direct free serum copper” for patients with WD with low levels of ceruloplasmin. Another assay proposed to evaluate NCC is the determination of the “exchangeable copper” (CuEXC) in serum. For this measurement, the chelating agent ethylenediamine tetraacetic acid (EDTA) is added to the serum sample; the copper content of the EDTA-bound fraction is measured. Quantification of CuEXC has been proposed as a method for estimating bioavailable NCC in the circulation.<sup>[148,149]</sup> For diagnostic purposes, the ratio of CuEXC to total serum copper, called the “relative exchangeable copper” (REC), with the cutoff set at 18.5%, distinguishes patients with WD from simple heterozygotes and normal individuals and also from adults and children with various chronic liver diseases.<sup>[143,150]</sup> Further validation of these methods by other clinical research groups is warranted.

## Basal 24-h urinary copper excretion

Measuring the amount of copper excreted in the urine in a 24-h period may be very helpful for diagnosing WD. The basal 24-h urinary excretion of copper reflects the amount of NCC in the circulation. Basal measurements provide useful diagnostic information so long as copper does not contaminate the collection apparatus and the urine collection is complete. Spot urine specimens are not suitable, except possibly with ALF, where extremely high spot urine copper concentrations suggest a diagnosis of WD. Volume and total creatinine excretion in the 24-h urine collection are measured to assess completeness. The conventional cutoff taken as diagnostic of WD is >100 µg/24 h (>1.6 µmol/24 h) in symptomatic patients<sup>[74,151]</sup>; however, this level may miss 16%–23% with WD.<sup>[15,76,77]</sup> Taking the cutoff as 40 µg (0.6 µmol) per 24 h, which is the upper limit of normal



in some laboratories, appears to be better.<sup>[71,152]</sup> When examined systematically in children, 40 µg/24 h is the best cutoff.<sup>[153,154]</sup>

Interpreting basal 24-h urinary copper excretion for diagnostic purposes can be difficult because of overlapping findings in other liver diseases. In certain chronic liver diseases, typically cholestatic but including AIH, basal 24-h urinary copper excretion may run 100–200 µg/24 h (1.6–3.2 µmol/24 h).<sup>[142,155]</sup> Primary sclerosing cholangitis is sometimes difficult to distinguish from WD based on basal urinary copper excretion data.<sup>[144,156]</sup> The same consideration may apply to children reported to have AIH<sup>[133]</sup>; they may have had autoimmune cholangitis. Patients with chronic cholestasis due to multidrug-resistance protein 3 (MDR3) deficiency may have elevated urinary excretion of copper.<sup>[157–160]</sup> In disorders where nonselective proteinuria wastes ceruloplasmin, basal urinary copper excretion may be elevated to levels >100 µg/24 h in the absence of elevated NCC.<sup>[161]</sup> Some simple heterozygotes with one pathogenic *ATP7B* variant have intermediate levels ranging 50–120 µg/24 h.<sup>[151,162]</sup>

Urinary copper excretion provoked by D-penicillamine administration (D-penicillamine challenge test) might be an adjunctive diagnostic test. This test has been standardized only in a pediatric population,<sup>[75]</sup> in which 500 mg of D-penicillamine was administered orally at the beginning and again 12 h later during the 24-h urine collection, irrespective of body weight. A clear differentiation from various other liver disorders was found when >1600 µg copper/24 h (> 25 µmol/24 h) was excreted. Recent re-evaluation showed that this test is not sufficiently sensitive in asymptomatic patients with WD.<sup>[163]</sup> Others have found the predictive value of the 25 µmol/24-h cutoff to be <100%.<sup>[153,164]</sup> This test has been used in adults, but those test protocols are nonuniform and not validated.<sup>[15,151,155]</sup>

Measurement of the basal 24-h urinary excretion of copper forms part of the assessment to screen first-degree relatives for WD. It should not be used as the sole test for screening asymptomatic individuals.

## Radiocopper study

The basis for this test is the decrease in radiocopper incorporation into ceruloplasmin in WD. Failure to incorporate radiocopper into apoceruloplasmin occurs in all patients with WD but rarely in nonaffected carriers. The radiocopper test was limited by logistical challenges related to isotope. Although challenges remain, advances in test design and standardization have improved its diagnostic accuracy and expanded its use for all patients with WD.<sup>[165]</sup> It may be useful diagnostically when the genotype found is difficult to evaluate or contains a variant of unknown significance. Methodology utilizing copper-65, a nonradioactive

isotope for copper, has proven less effective for distinguishing heterozygote carriers from individuals with WD<sup>[166,167]</sup> and is not routinely available.

## Liver biopsy

Liver biopsy allows quantification of hepatic copper deposition and assessment of grade and stage of liver injury. It aids in exclusion of other liver diseases. Follow-up biopsy, including quantification of parenchymal copper concentration, may be useful in select cases.<sup>[168]</sup>

## Liver biopsy findings

Histologic findings in liver biopsies in WD are often nonspecific. Early changes include mild steatosis, with very small fat droplets at first, increasing to accumulation of larger fat droplets: these findings mimic mild NAFLD. Hepatocyte swelling with spotty hepatocyte necrosis and small collections of lymphocytes in the parenchyma is an early, nonspecific finding.<sup>[169,170]</sup> The changes are often scattered throughout the lobule but may be more pronounced in the periportal areas.<sup>[169]</sup> An AIH-like pattern of injury may be present, with parenchymal mononuclear inflammatory infiltrate and interface hepatitis. Portal and periportal fibrosis may progress to portal-portal bridging and finally cirrhosis. The cirrhosis is typically coarsely nodular; in late stages, hepatocytes vary greatly in size and show prominent ballooning degeneration and Mallory–Denk bodies. Enlarged hepatocytes with granular eosinophilic cytoplasm due to a large number of mitochondria (oncocyctic cells) may be present.<sup>[171]</sup> With ALF due to WD, the liver shows multilobular confluent necrosis, almost always superimposed upon cirrhosis, that has no distinguishing features, although abundant glycogen-rich nuclei with relatively mild steatosis may suggest the diagnosis, and numerous apoptotic hepatocytes may be seen.<sup>[172]</sup>

Copper is heterogeneously deposited in the liver in WD, varying from lobule to lobule early in the disease and from nodule to nodule in cirrhosis. This variability may lead to negative staining results for copper deposition, especially in small samples. Early in WD, excess copper is predominantly bound to metallothionein and is diffusely distributed in the cytoplasm, not amenable to histochemical detection.<sup>[173]</sup> Later in the course of the disease, hepatocellular copper becomes concentrated in lysosomes as well as located in the cytoplasm. Copper in lysosomes can be detected with histochemical stains such as rhodanine (the most commonly used stain), rubeanic acid, or the modified Timm's stain, which is more sensitive but used less often.<sup>[174]</sup> Shikata-type stains, such as orcein and aldehyde fuchsin, detect increased copper-binding protein(s) and may be used as a surrogate for detection of

increased copper. Because histochemical stains for copper in general have poor sensitivity and a negative stain does not exclude the diagnosis of WD,<sup>[174]</sup> quantitative copper analysis of the liver biopsy is preferred. Histochemically detected hepatocellular copper provides a clue to diagnosis of WD and may be particularly helpful in the context of ALF.

Ultrastructural abnormalities in hepatocellular mitochondria are highly characteristic of WD,<sup>[175]</sup> notably in pediatric patients.<sup>[176]</sup> Typical findings include variability in size and shape, increased density of the matrix material, numerous inclusions including lipid, and fine granular material, which may be copper and copper-binding proteins.<sup>[177]</sup> The most striking alteration in mitochondrial structure is increased intracristal space with dilatation of the tips of the cristae, creating a cystic appearance. At later stages of the disease, dense deposits within lysosomes are present. With adequate treatment, these mitochondrial changes may resolve.

Although hepatocellular carcinoma (HCC) has been regarded as a rare complication of WD, it may be more frequent than previously recognized. Liver biopsy has a role in characterizing hepatic neoplasia complicating WD, including distinction of HCC and intrahepatic cholangiocarcinoma (CCA).

## Hepatic parenchymal copper concentration

Normal hepatic copper content is <50 µg/g dry weight. In most but not all cases of WD, hepatic copper content is greatly elevated: >250 µg/g dry weight is generally the reference value. A threshold value of 75 µg/g was proposed to increase test sensitivity.<sup>[30]</sup> Another large study proposed 209 µg/g dry weight as having a sensitivity of 99% and specificity of 96%.<sup>[178]</sup> The concentration of hepatic copper in simple heterozygotes, although frequently elevated above normal, is usually <250 µg/g dry weight.<sup>[179]</sup> Hepatic copper also accumulates with chronic cholestatic disorders and cirrhosis, typically not to WD levels.<sup>[180]</sup> Indian childhood cirrhosis and other idiopathic copper toxicosis syndromes are also characterized by very high levels of hepatic copper.<sup>[181,182]</sup>

Biopsies for quantitative copper determination should be taken with a disposable suction or cutting needle and placed without additional liquid in a copper-free container. To prevent autolysis, a core (or part of a biopsy core) of liver should be frozen immediately or vacuum-dried for shipment to a laboratory for quantitative copper determination, according to the direction of the local laboratory. Paraffin embedded specimens can be analyzed for copper content but require additional laboratory processing.

Because hepatic copper is irregularly distributed in the parenchyma in WD, analysis of liver biopsies may result in underestimation of the copper content, especially in the setting of cirrhosis. To overcome the problem of

sampling error, performing two biopsy passes has been proposed,<sup>[183]</sup> with one core devoted entirely to analysis of hepatic copper concentration.<sup>[178]</sup> Accuracy and precision of measurement are related to sample size; a decrease in accuracy of 15% has been reported for sample weights of less than 3 mg, with further decreases with decreasing weight of the biopsy.<sup>[184]</sup> Reported pediatric experience indicates that measuring hepatic copper content is reliable, based on data with a single biopsy core.<sup>[185]</sup> A minimum biopsy dry weight of 3 mg<sup>[183]</sup> or at least 1–2 cm long<sup>[186]</sup> should be submitted for analysis. Transjugular liver biopsy has largely circumvented technical problems associated with obtaining a liver biopsy in patients with decompensated cirrhosis or severe coagulopathy; however, multiple samples may be required due to the small diameter of the biopsy needle. Measurement of hepatic parenchymal copper concentration is most important in younger patients in whom hepatocellular copper is mainly cytoplasmic and thus undetectable by routine histochemical methods.

The most commonly used technique for measuring hepatic copper has been atomic absorption spectroscopy, but this method is being supplanted in many reference laboratories by quantitative inductively coupled plasma mass spectroscopy (ICP-MS). Laser-ablation ICP-MS, used in the research setting, allows imaging of the spatial distribution of copper within liver tissue<sup>[187,188]</sup> and highlights its heterogeneous distribution.

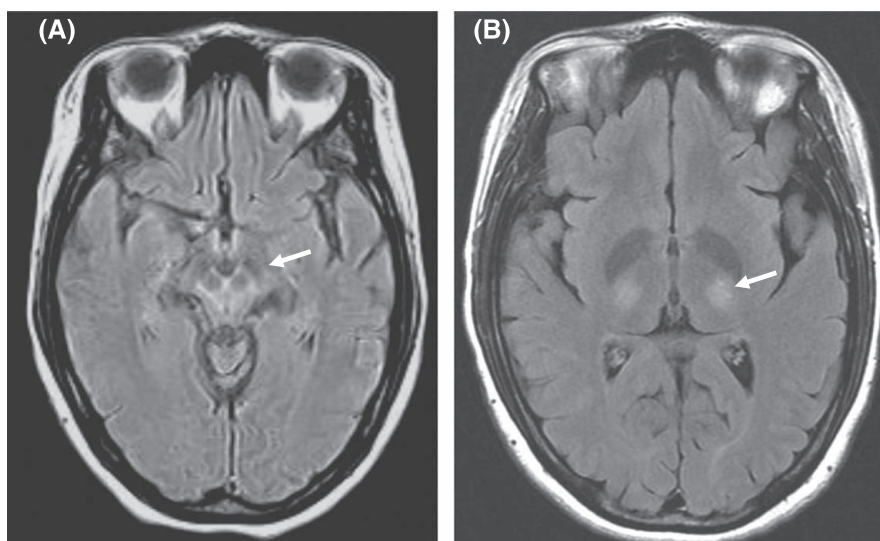
## Imaging of the brain

### Magnetic resonance imaging (MRI)

MRI of the brain can be helpful in establishing a diagnosis for patients with unexplained neurological and psychiatric symptoms and frequently reveals findings consistent with WD. MRI findings include signal changes in the basal ganglia, thalami, pons, and white matter, as well as atrophy.<sup>[189]</sup> The so-called “face of the giant panda sign,” which consists of increased T2 signal in the midbrain (Figure 1), has been considered pathognomonic for WD, but several other findings are more commonly seen. MRI findings typical of WD must be distinguished from changes associated with end-stage chronic liver disease. Patients with extensive changes on brain imaging, such as evidence of tissue cavitation, are less likely to improve with treatment.<sup>[190]</sup> In general, repeated MRIs are not useful for determining prognosis or monitoring neurological progression.

### Computerized tomography (CT) and other radiologic imaging

CT of the brain has limited utility for assessing WD, although it can reveal/exclude other significant CNS



**FIGURE 1** Magnetic resonance images of a 32-year-old woman with Wilson disease. (A) Flair image of the midbrain showing the “face of the giant panda sign” (arrow). (B) T2 image showing thalamic lesions (arrow).

disease. Other imaging modalities, including single-photon emission computed tomography and positron emission tomography scans, offer no additional information besides that obtained by MRI for diagnosing WD but may be used to evaluate patients unable to undergo MRI. Significant abnormalities on brain imaging may be present in some individuals prior to the onset of symptoms.<sup>[191,192]</sup>

#### Guidance statements 6–10

6. Once WD is considered, a detailed personal and family medical history should be conducted and a physical examination focused on evidence of liver, neurological, and psychiatric disease performed. Assessment should include the following:
  - liver biochemistries;
  - complete blood count and international normalized ratio (INR);
  - serum ceruloplasmin and, in some patients, serum copper;
  - basal 24-h urinary copper excretion;
  - slit-lamp or optical tomography examination for KF rings;
  - neurological evaluation; and
  - molecular genetic investigation of *ATP7B* (depending on logistics).
7. An extremely low serum ceruloplasmin level (<5 mg/dl) more strongly suggests a diagnosis of WD than modestly subnormal levels. Serum ceruloplasmin by itself is insufficient for making a diagnosis of WD. Serum ceruloplasmin within the normal range does not exclude the diagnosis of WD.

8. Basal 24-h urinary excretion of copper in WD is typically >100 µg/24 h (> 1.6 µmol/24 h) in symptomatic patients, but a lower reference value of >40 µg/24 h (> 0.6 µmol/24 h) may indicate WD in asymptomatic individuals or children and therefore requires clinical correlation and further investigation.
9. Liver biopsy for histology can aid in the diagnosis of WD by identifying findings consistent with WD and permitting disease staging/grading. It may also suggest an alternative or concurrent diagnosis of liver disease. It allows quantification of liver tissue copper. Hepatic parenchymal copper content more than >250 µg/g dry weight occurs in most patients; a lower content still above normal occurs less frequently but should prompt other confirmatory testing. In untreated patients, normal hepatic copper content (<50 µg/g dry weight) almost always excludes a diagnosis of WD. Electron microscopic evaluation of liver tissue may aid diagnosis of WD, notably in pediatric patients.
10. If neurological evaluation reveals abnormalities, radiologic imaging of the brain, preferably by MRI, should be considered to establish baseline status and exclude other potential causes.

#### Genetic studies

WD, inherited in an autosomal recessive manner, is associated only with mutations in *ATP7B*, a relatively

large gene (21 exons, 4.1-kb coding region) located on the short arm of chromosome 13. Numerous gene variants in *ATP7B* are documented, with at least 380 pathogenic gene variants or as many as 732 associated with WD, depending on the database and extent of updating.<sup>[14]</sup> The most common gene changes are missense mutations, deletions, or insertions. These alterations occur in nearly all 21 exons of *ATP7B*.<sup>[83]</sup> Most patients are compound heterozygotes harboring different mutations on each allele.

The commonly reported general prevalence of WD is 1:30,000.<sup>[9,134]</sup> A recent study operating from an extremely large administrative database in California broadly supports this figure.<sup>[102]</sup> A recent comprehensive systematic review put the disease prevalence at 1:30,000–1:50,000, higher in populations where first-cousin marriages are frequent.<sup>[10]</sup> Population-based genetic studies suggest that the general prevalence might be higher. The prevalence of individuals with two disease-causing *ATP7B* mutations is conceivably 1:7026 in the United Kingdom.<sup>[11]</sup> Recent studies based on large databases have put the general prevalence at >1:30,000.<sup>[14,193]</sup> One study, attempting to bridge the discrepancy of allele prevalence and clinical WD, puts the general prevalence of WD at 1:20,000 and specifies differing prevalence according to ethnic or geographic group.<sup>[14]</sup> Prevalence of simple carriers (a single pathogenic variant; unaffected by WD) is approximately 1:90, possibly an underestimate in some populations.<sup>[12,13]</sup> Isolated populations tending to be endogamous may have a higher prevalence of both WD and simple carriers than elsewhere.

Genetic testing for *ATP7B* mutations is available in many certified clinical laboratories; however, analytic techniques may vary from one laboratory to another. Direct mutational analysis is useful for detecting mutations in first-degree relatives of a patient (the proband) with a known genotype with two disease-specific mutations that are trans, one on each allele of chromosome 13. Genetic analysis is a valuable diagnostic strategy for certain well-defined populations exhibiting a limited spectrum of *ATP7B* mutations, such as in Sardinia,<sup>[194]</sup> Iceland,<sup>[195]</sup> Korea,<sup>[196]</sup> Japan,<sup>[197]</sup> Taiwan,<sup>[198]</sup> Spain,<sup>[199]</sup> and the Canary Islands.<sup>[152]</sup> More than half of the patients with WD who are from Northern, Central, and Eastern Europe carry at least one allele with the p.H1069Q mutation in exon 14.<sup>[199–202]</sup> Limited or selective mutational analysis can fail to detect some genetic abnormalities. The preferred technique is direct analysis of the entire *ATP7B* gene, including its promoter region, with attention to intron/exon boundaries and possible occurrence of large deletions. The sensitivity of sequencing the entire gene is >99% for detecting nucleotide base pair changes, small deletions, and insertions in the coding region. Application of whole-exome sequencing or whole-genome sequencing is gaining favor; however, mutations in the untranslated regions, large deletions of whole exons, large insertions, and rare genetic recombinations may not be detected by next-generation (massively parallel) sequencing. Cost may

also be an issue. Nevertheless, targeted next-generation sequencing may prove best overall.<sup>[203]</sup> Other high-throughput methods include denaturing high performance liquid chromatography and automated single-stranded conformation polymorphism analysis. In some cases, both DNA and RNA may need to be analyzed in order to identify a large deletion that would otherwise be overlooked.<sup>[204]</sup>

Genetic analysis of *ATP7B* remains a diagnostic test and at present does not predict disease course. Mutations affecting critical portions of the protein including copper-binding domains or the ATPase loop may lead to early onset of hepatic disease,<sup>[205]</sup> and truncating mutations may be associated with ALF.<sup>[206,207]</sup> In Chinese patients, p.P992L or p.N1270S was associated with presentation before age 12, and p.I1148T occurred almost exclusively in patients presenting after 12 years-old.<sup>[208]</sup> Importantly, there are no firm genotype–phenotype correlations.<sup>[209]</sup> Increasing evidence indicates that epigenetic factors, such as global DNA hypomethylation, and environmental factors, such as dietary intake of copper, may contribute to pathogenesis and clinical presentation.<sup>[210,211]</sup> Modifier genes have been proposed,<sup>[212,213]</sup> associated with milder clinical phenotypes.

Genetic studies are useful in several clinical scenarios. In patients for which the diagnosis is uncertain, sequencing the *ATP7B* gene can confirm WD if pathogenic gene variants are found on both alleles. In addition, sequencing *ATP7B* can be performed in a proband and then used for targeted mutational analysis in first-degree relatives. If genotype analysis is not feasible, haplotype analysis (patterns of single nucleotide polymorphisms around the *ATP7B* locus) in the proband can permit evaluating first-degree relatives without actually identifying the *ATP7B* mutation(s).<sup>[214]</sup> Genotype analysis is essential for distinguishing WD from other genetic-metabolic disorders with similar phenotypic features, notably MDR3 deficiency. Interpreting results of genotype analysis in WD can be complicated. Various resources are available for assessing pathogenicity of a specific *ATP7B* variant (Table 4). Input from a clinical geneticist may be extremely valuable for such interpretation, particularly for variants identified as being of unknown significance. Genetic counseling to help explain testing results and their current and future implications to the patient and family complements discussions with other clinical providers.

### Guidance statement 11

11. Genetic testing for *ATP7B* mutations may be performed as part of a routine evaluation. It can provide diagnostic confirmation when biochemical testing is not definitive. It is efficient for screening first-degree relatives of a proband.



**TABLE 4** Resources available for evaluating *ATP7B* gene variants

	URL	Comments
<i>Public domain databases</i>		
ClinVar	<a href="https://www.ncbi.nlm.nih.gov/clinvar/">https://www.ncbi.nlm.nih.gov/clinvar/</a>	National Center for Biotechnology Information (NCBI)
gnomAD	<a href="https://gnomad.broadinstitute.org/">https://gnomad.broadinstitute.org/</a>	
VarSome	<a href="https://landing.varsome.com/varsome-clinical">https://landing.varsome.com/varsome-clinical</a>	
<i>Proprietary databases</i>		
Human Gene Mutation Database	<a href="http://www.hgmd.org">http://www.hgmd.org</a>	University of Cardiff <sup>[433]</sup>
WilsonGen	<a href="https://clingen.igib.res.in/WilsonGen/">https://clingen.igib.res.in/WilsonGen/</a>	CSIR Institute of Genomics and Integrative Biology, Delhi <sup>[434]</sup>
University of Alberta Wilson Disease Mutation Database	(Previously) <a href="http://www.medgen.med.ualberta.ca/database.html">www.medgen.med.ualberta.ca/database.html</a>	Limited or no access at the present time <sup>[435]</sup>

Abbreviations: *ATP7B*, ATPase copper transporting beta (gene associated with Wilson disease); CSIR, Council of Scientific and Industrial Research.

## SPECIFIC DIAGNOSTIC CHALLENGES RELATING TO WD

### “Mimic” liver diseases

Hepatic disorders resembling WD include those that mimic WD clinically and thus are prominent in the differential diagnosis and those that are mechanistic mimics (Table 5). The latter are rare disorders.

### Clinical mimics in the differential diagnosis of WD

#### AIH

Patients with WD, especially younger ones, may have clinical features and histologic findings on liver biopsy indistinguishable from AIH.<sup>[28]</sup> WD should be excluded in children with apparent AIH. Any patient with the presumptive diagnosis of AIH failing to respond rapidly and appropriately to corticosteroid treatment should be evaluated for WD. In rare patients, concurrent WD and AIH cannot be excluded and indeed may coexist, necessitating treatment for both disorders.<sup>[215]</sup>

#### NAFLD

Hepatic steatosis in WD may be as severe as in NAFLD; notably, children may have extensive steatosis without prominent hepatic inflammation in either disorder. WD may have histological features of NASH, including Mallory–Denk bodies. Differentiation of WD from NAFLD may be possible via measurement of basal 24-h urinary copper excretion, which is low in NAFLD<sup>[30,216]</sup> and by hepatic copper determination. In general, hepatic parenchymal copper content is strikingly low in NAFLD compared with WD.<sup>[185,217,218]</sup> Serum ceruloplasmin may run toward low-normal in NAFLD, but it rarely achieves subnormal values or low concentrations suggestive of WD<sup>[219]</sup> (E. A. Roberts

and D. R. Mager, unpublished observations, 2019). Given the increased prevalence of obesity, concurrence of these diseases may become more common in patients with WD.

#### Aceruloplasminemia

Aceruloplasminemia, due to mutations in the structural gene for ceruloplasmin on human chromosome 3, is an extremely rare disorder that may present with neurological disturbances including ataxia, dysarthria, dystonia, and parkinsonian movement disorder.<sup>[220,221]</sup> Clinical presentation is typically in adulthood.<sup>[222]</sup> The pathogenesis involves iron accumulation in the CNS. The liver biopsy often shows iron overload but no copper accumulation.<sup>[222–226]</sup> Serum ceruloplasmin is absent. Clear distinction from WD is based on genetic analysis.

#### MDR3 deficiency

Abnormalities in expression or function of the bile canalicular transporter MDR3 cause a chronic cholestatic disease (also known as progressive familial intrahepatic cholestasis type 3 [PFIC3]) with elevated hepatic copper and increased urinary copper excretion meeting diagnostic thresholds for WD according to the Leipzig score.<sup>[157–160]</sup> Typically, serum ceruloplasmin is normal, and genetic studies reveal pathologic variants in the relevant gene ATP-binding cassette subfamily B member 4 (*ABCB4*) but none in *ATP7B*.

#### Congenital disorders of glycosylation

In some of these highly heterogeneous disorders, known as congenital disorders of glycosylation (CDGs), serum ceruloplasmin is low and liver biochemistries abnormal. Hepatic copper concentrations are moderately elevated (typically >50 but <250 µg/g dry weight tissue), but basal 24-h urinary copper excretion is normal. Phosphoglucomutase 1 deficiency (PGM1-CDG) produces this clinical picture.<sup>[227,228]</sup> Its clinical features contrast WD: cleft uvula,

**TABLE 5** Rare genetic diseases resembling WD

Disorder	Gene	Serum ceruloplasmin	Hepatic Cu	24-h basal urinary Cu	Possible mechanism(s)	Type <sup>a</sup>
Aceruloplasminemia	<i>CP</i>	Absent	Normal; ↑Fe	Normal	No production of ceruloplasmin	Clinical
MDR3 deficiency	<i>ABCB4</i>	Normal	↑	May be ↑	Copper retention due to cholestasis	Clinical
MEDNIK syndrome <sup>b</sup>	<i>AP1S1</i>	Very low	May be ↑	↑ (2.5 μmol /24 h)	Protein production + metal (Cu) excretion abnormality	Mechanistic
Mn retention–1 <sup>c</sup>	<i>SLC30A10</i>	Normal	Slightly ↑	??	Hepatic Mn excretion abnormality	Mechanistic
Mn retention–2 <sup>c</sup>	<i>SLC39A14</i>	Not reported			Hepatic Mn uptake abnormality	Mechanistic
Nieman–Pick type C <sup>d</sup>	<i>NPC1</i> , <i>NPC2</i>	Low or slightly low	Mildly ↑ (between 100 and 250 μg/g dry weight)	Normal	Defective interaction with ATP7B	Mechanistic
PGM1-CDG	<i>PGM1</i>	Low	Mildly ↑ (between 50 and 250 μg/g dry weight)	Normal	(Golgi dysfunction)	Clinical, mechanistic
CCDC115-CGD <sup>e</sup>	<i>CCDC115</i>	Low or very low	Slightly ↑	Normal or mildly ↑	Abnormality in protein production pathway affecting ATP7B function (Golgi dysfunction)	Clinical, mechanistic
TMEM119-CDG <sup>e</sup>	<i>TMEM199</i>	Low	Not reported	Normal or mildly ↑	(Golgi dysfunction)	Clinical, mechanistic

Abbreviations (except column 2, "Gene"): CDG, congenital disorder of glycosylation; Cu, copper; Fe, iron; MEDNIK, intellectual (Mental) disability, enteropathy, deafness, neuropathy, ichthyosis, keratoderma; Mn, manganese; PGM1, phosphoglucomutase 1; WD, Wilson disease.

Abbreviations for genes (column 2): *ABCB4*, ATP-binding cassette subfamily B member 4; *AP1B1*, adaptor related protein complex 1 subunit beta 1; *AP1S1*, adaptor-related protein complex 1 subunit sigma 1; *ATP7B*, ATPase copper transporting beta; *CCDC115*, coiled-coil domain containing 115; *CP*, ceruloplasmin; *MDR3*, multidrug-resistance protein 3; *NPC1*, NPC intracellular cholesterol transporter 1; *NPC2*, NPC intracellular cholesterol transporter 2; *SLC30A10*, solute carrier family 30 member 10; *SLC39A14*, solute carrier family 39 member 14; *TMEM119*, transmembrane protein 119.

<sup>a</sup>See text for definition of type.

<sup>b</sup> MEDNIK syndrome displays very low serum ceruloplasmin, elevated basal 24-h urinary copper excretion, and hepatic copper retention; neurological features are atypical for WD, including severe intellectual disability, deafness, and peripheral neuropathy. A related disorder associated with mutations in *AP1B1* has low serum copper and ceruloplasmin but no evident hepatic damage.

<sup>c</sup>Both disorders of manganese transport can present in childhood with a parkinsonian movement disorder; the *SLC30A10* disorder may also have hepatic involvement (fatty liver, cirrhosis); brain magnetic resonance imaging findings differentiate from WD.

<sup>d</sup>Clinical findings in Niemann–Pick type C are mainly neurological; serum ceruloplasmin may be subnormal.

<sup>e</sup>Clinical findings may include neurological disorder and dyslipidemia. In PGM1-CDG, clinical features are distinctly unlike WD.

rhabdomyolysis, dilated cardiomyopathy, and hypoglycemia. Recently, CCDC115-CDG was identified as associated with hepatic copper overload with features suggestive of WD including hepatosplenomegaly, and psychomotor disability and/or hypotonia.<sup>[229,230]</sup> Similarly, transmembrane protein 119-CDG may generate a phenotype including neurodevelopmental abnormalities, elevated serum aminotransferases, low serum ceruloplasmin, and dyslipidemia.<sup>[231]</sup> Other glycosylation disorders resembling WD may yet be identified. Golgi dysfunction may account for the phenotypic similarities to WD. Primary diagnosis of CDGs is by transferrin isoelectric focusing; more specific screens are being developed. Next-generation sequencing is critical to identifying these disorders. Differentiation of WD from any CDG avoids inappropriate treatment for WD in a patient with CDG and may permit treatment targeted at the particular CDG, for example, galactose supplementation for PGM1-CDG.

## Mechanistic (etiopathogenic) mimics of WD

Several very rare genetic disorders (for details, see Table 5) qualify on the strict criterion of having similarity in disease mechanism: MEDNIK (intellectual (Mental) disability, enteropathy, deafness, neuropathy, ichthyosis, keratoderma) syndrome (mutations in adaptor-related protein complex 1 subunit sigma 1 [*AP1S1*]), two separate manganese retention disorders (mutations in solute carrier family 30 member 10 [*SLC30A10*] or in solute carrier family 39 member 14 [*SLC39A14*]), and Niemann–Pick type C. These disorders implicate the ATP7B interactome or are metal-transport disorders.

## ALF due to WD

Most who present with ALF due to WD typically have the following characteristic pattern of clinical and biochemical findings<sup>[232–235]</sup>:

- severe Coombs-negative hemolytic anemia (acute intravascular hemolysis);
- coagulopathy unresponsive to parenteral vitamin K administration;
- relatively modest rises in serum aminotransferases (typically <2000 IU/L) from onset of clinical illness;
- normal or markedly subnormal serum alkaline phosphatase (typically <40 IU/L)<sup>[119]</sup>;
- rapid progression to renal failure;
- female:male ratio of >2:1 to 4:1.<sup>[202]</sup>

Although pediatric patients frequently show these classic features, their presentation as ALF may be less distinctive.<sup>[236]</sup> Hepatic encephalopathy may be

evident at presentation or develop over the next few days.

Expedition diagnosis is critically important because these patients require urgent evaluation for liver transplantation. In both adults and children, ALF due to WD carries a high mortality (80%–99%) without liver transplantation.<sup>[237]</sup> The modest elevation of serum aminotransferases compared with ALF of other etiologies often causes an underestimation of disease severity. There is a spectrum of injury from ALI to ALF with hepatic encephalopathy. The presence of hepatic encephalopathy presages a poor outcome.<sup>[234–236]</sup>

The usual diagnostics for WD differ in ALF. KF rings, if present, support the diagnosis but are absent in 50%. Other rare findings, like lunulae ceruleae, should suggest further evaluation to exclude WD. In most patients with ALF due to WD, serum AST is higher than serum ALT, potentially reflecting mitochondrial damage, but this finding is not diagnostic.<sup>[72,237]</sup> Serum ceruloplasmin is usually decreased, but its predictive value in this setting is poor.<sup>[145]</sup> Serum copper and 24-h urinary excretion of copper are greatly elevated. The serum copper is usually >200 µg/dL.<sup>[145]</sup> These copper results are often not available in a timely manner, and diagnosis relies on clinical and biochemical features.

The study by Korman et al.<sup>[145]</sup> explored how best to establish a diagnosis of ALF due to WD using standard biochemical parameters. A ratio of alkaline phosphatase to total bilirubin of <4 was 94% sensitive and 96% specific, whereas a ratio of AST to ALT >2.2 was 94% sensitive but only 86% specific. The combination of both ratios (alkaline phosphatase to total bilirubin <4 and AST to ALT >2.2) was 100% sensitive and 100% specific for diagnosing WD in their cohort. This diagnostic approach appears to work less well for identifying ALF due to WD in the pediatric age bracket.<sup>[236,238]</sup>

When ALF is the first presentation of WD, underlying liver disease is not suspected. Cirrhosis is typically, not inevitably, present.<sup>[72]</sup> An intercurrent illness such as a viral infection<sup>[239]</sup> or drug toxicity may trigger ALF due to WD. Rare patients develop ALF from viral hepatitis and are found to have underlying WD.<sup>[240,241]</sup>

Recognition of ALF due to WD is important so that other first-degree relatives may then be screened for this disorder. Thus, liver failure or death from WD can be prevented in these individuals.

## DIAGNOSTIC STRATEGIES FOR SYMPTOMATIC WD

A methodical approach may facilitate diagnosis of WD. Accordingly, algorithms provide a structured approach to diagnosis. Different clinical presentations demand different algorithms. Alternatively, an arithmetic “scoring

system,” such as the Leipzig score,<sup>[117]</sup> uses weighted scores for parameters valuable for disease diagnosis. The two may be complementary, as illustrated in the algorithms provided.

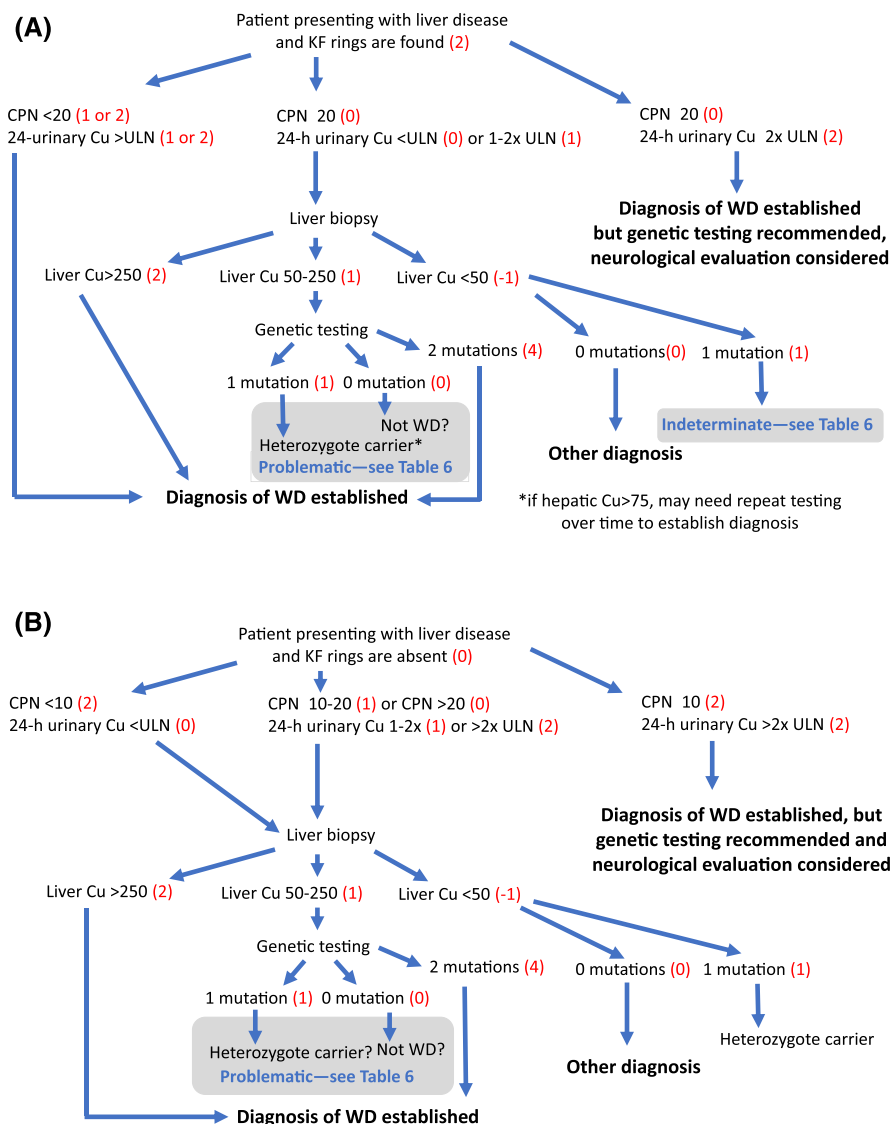
## Algorithms to facilitate diagnosis of symptomatic WD

Approaches for diagnosing WD presenting as hepatic disorder are in [Figure 2A,B](#), and approaches for diagnosing neurologic WD are in [Figure 3A,B](#). Algorithms can serve two purposes: expedite diagnosis

or identify situations where diagnosis is complicated. In [Figures 2 and 3](#), such situations are portrayed as “gray zones.” [Table 6](#) is an annex to [Figures 2–4](#), providing a checklist of key considerations for the approach to sorting out situations characterized as being in the “gray zone.”

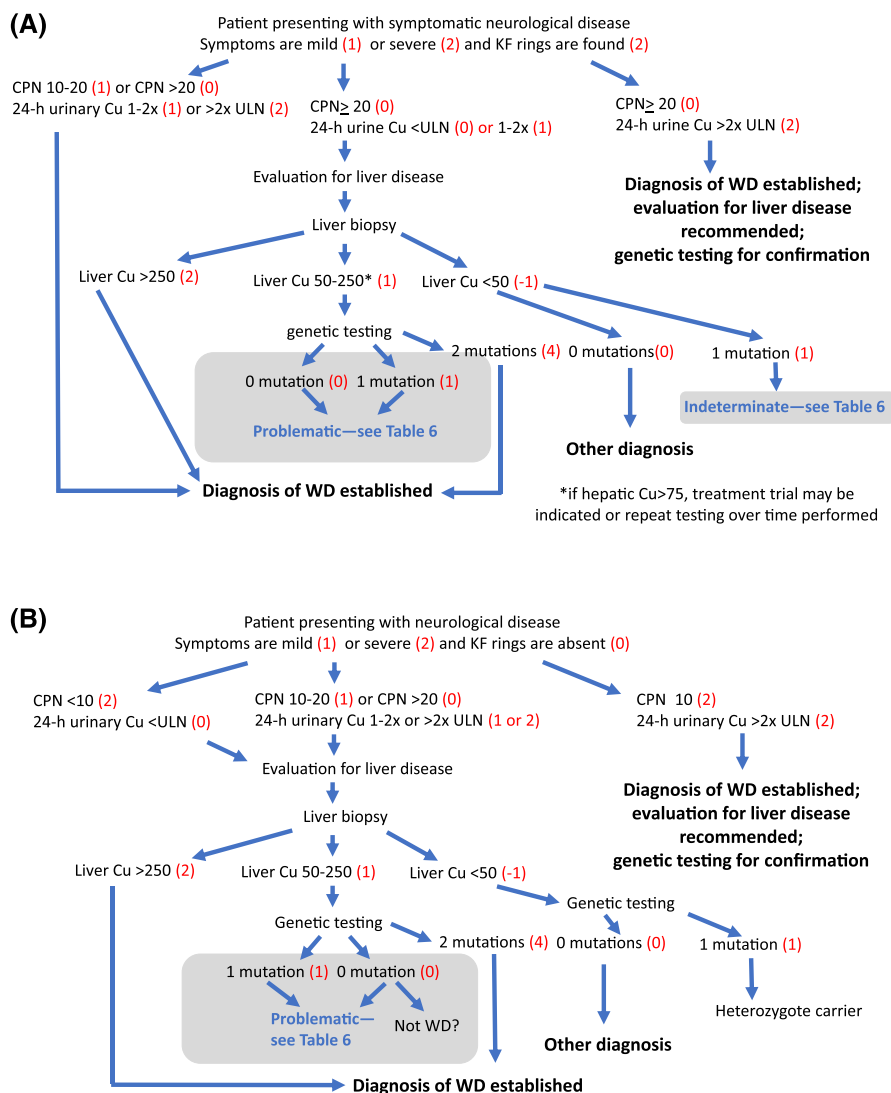
## Scoring systems

Diagnostic scoring systems include the Leipzig score for general diagnosis and several biochemical indices for identifying ALF due to WD. The first prognostic score



**FIGURE 2** Algorithmic approach to diagnosis of Wilson disease (WD) in a patient with unexplained liver disease: (A) KF rings found and (B) KF rings absent. Baseline testing consists of serum ceruloplasmin (CPN), basal 24-h urinary Cu, and slit-lamp examination or optical tomography. Minimum ULN for basal 24-h urinary Cu is taken as 40 µg/24 h. Genetic testing means analyzing ATPase copper transporting beta (*ATP7B*) sequence to establish presence on each allele of a disease-associated mutation. Gray zones identify situations where algorithm mandates critical review—see [Table 6](#). Numbers in parentheses indicate corresponding Leipzig score, where a sum  $\geq 4$  indicates that WD is highly likely. Assignment of points according to Leipzig score: CPN (mg/dl) normal  $>20 = 0$ ,  $10-20 = 1$ ,  $<10 = 2$ ; KF rings present = 2, absent = 0; basal 24-h urinary Cu (µg/24 h)  $<ULN = 0$ ,  $1-2 \times ULN = 1$ ,  $>2 \times ULN = 2$ ; liver Cu (µg/g dry wt liver)  $>5 \times ULN = 2$ ,  $50-250 = 1$ ,  $<50 = -1$ ; genetic testing: two disease-associated mutations = 4, one disease-associated mutation = 1. CPN, ceruloplasmin; Cu, copper; KF, Kayser–Fleischer; ULN, upper limit of normal.





**FIGURE 3** Algorithmic approach to diagnosis of Wilson disease (WD) in a patient with a neurological disorder: (A) KF rings found and (B) KF rings absent. Presentation of WD as a neurological disorder without KF rings is rare but poses important challenges diagnostically. Baseline testing consists of serum ceruloplasmin (CPN), basal 24-h urinary Cu, and slit-lamp examination or optical tomography. Minimum ULN for basal 24-h urinary Cu is taken as 40 µg/24 h. Genetic testing means analyzing ATPase copper transporting beta (*ATP7B*) sequence to establish presence on each allele of a disease-associated mutation. Gray zones identify situations where algorithm mandates critical review—see Table 6. Numbers in parentheses indicate corresponding Leipzig score, where a sum ≥ 4 indicates that WD is highly likely. Assignment of points according to Leipzig score: CPN (mg/dl) normal >20 = 0, 10–20 = 1, <10 = 2; KF rings present = 2, absent = 0; basal 24-h urinary Cu (µg/24 h) <ULN = 0; 1–2× ULN = 1, >2× ULN = 2; liver Cu (µg/g dry wt liver) >5× ULN = 2, 50–250 = 1, <50 = -1; genetic testing: two disease-associated mutations = 4, one disease-associated mutation = 1. CPN, ceruloplasmin; Cu, copper; KF, Kayser–Fleischer; ULN, upper limit of normal.

was the Nazer score, superseded by the New Wilson Index (NWI). Importantly, all the scoring systems require prospective validation, periodic review, and possible revision. Concealed within all scoring systems are assumptions about the pathophysiology of organ involvement in WD. These assumptions may be altered with further clinical characterization of WD.

## Diagnostic scoring systems

### Leipzig score (for diagnosis of WD)

In 2001, WD experts gathering in Leipzig, Germany, generated a diagnostic scoring system, based on expert

opinion and available evidence, comprised of clinical and biochemical findings with a graded score for each,<sup>[117]</sup> shown in Table 7. This scoring system was the first to include genetic diagnosis of WD by analysis of *ATP7B* mutations. The scoring system was validated in adults<sup>[242–244]</sup> and children.<sup>[243,245]</sup> Its use in clinical studies ensures better standardization for enrolled patients.

Certain aspects of the original formulation of the Leipzig score are either ambiguous or difficult to interpret, particularly in relation to basal and D-penicillamine-provoked 24-h urinary copper excretion. The reference value for children was subsequently

**TABLE 6** Checklist for dealing with “gray areas” in the diagnostic algorithms provided

Type of problem	Specific issues	Action
Accuracy of laboratory data	Serum ceruloplasmin—known confounders	See <a href="#">Table 3</a>
	24-h urinary copper—incomplete collection or contamination	<ul style="list-style-type: none"> <li>• Confirm technical adequacy of assay</li> <li>• Check creatinine level</li> <li>• Repeat testing</li> </ul>
	Liver [Cu]—was specimen large enough? Stored properly?	Check report and/or discuss with pathologist
	Competence/completeness of genetic analysis	<ul style="list-style-type: none"> <li>• Review protocols</li> <li>• Consult clinical geneticist</li> <li>• Confirm trans (not cis) mutations</li> </ul>
Adequacy of clinical assessment	Neurological assessment	<ul style="list-style-type: none"> <li>• Expert review for specifying relevant findings</li> <li>• Brain MRI</li> </ul>
	Kayser–Fleischer rings	Repeat exam or optical tomography to determine whether present or not
	Psychiatric assessment (only implied in algorithms)	Expert consultation/review
Data available but not accounted for in algorithms	Liver biochemistries	<ul style="list-style-type: none"> <li>• Normal LFTs would likely preclude a liver biopsy</li> <li>• Abnormal LFTs support WD or some other liver disorder: biopsy may be performed</li> </ul>
	Liver histology	<ul style="list-style-type: none"> <li>• Findings may support WD or provide basis for alternative diagnosis</li> <li>• Consider examining ultrastructure (by EM) because findings may support WD, notably in children</li> </ul>
Emerging problems not well accounted for in algorithms	Hepatic Cu <250 µg/g dry weight but above suggested revisions of that threshold (e.g., >75 µg/g dry weight) and well above normal	<ul style="list-style-type: none"> <li>• Reevaluate, with genetic analysis if not yet performed</li> <li>• Treatment trial</li> </ul>
	Only one mutation found, but along with a VUS	<ul style="list-style-type: none"> <li>• Repeat clinical/biochemical evaluation in 6–12 months or until clear diagnosis is reached</li> <li>• In silico assessment of VUS</li> </ul>
	Screening reveals affected infant/toddler who is entirely healthy	Reevaluate every 6 months: plan to start treatment at 3 years-old unless earlier evidence of organ damage

Abbreviations: Cu, copper; EM, electron microscopy; LFT, biochemical liver test; MRI, magnetic resonance imaging; VUS, variant of unknown significance; WD, Wilson disease.

modified because basal 24-h urinary copper excretion is frequently 40–100 µg/24 h, below the more specific cutoff (>100 µg/24 h). Moreover, exceptions to the Leipzig criteria for diagnosing WD have emerged, including patients with aceruloplasminemia with neurological findings and no detectable serum ceruloplasmin and patients with MDR3 deficiency (PFIC3), with elevated hepatic and urine copper values.<sup>[157–160]</sup> Critical review of the data for these patients helps distinguish them from WD.

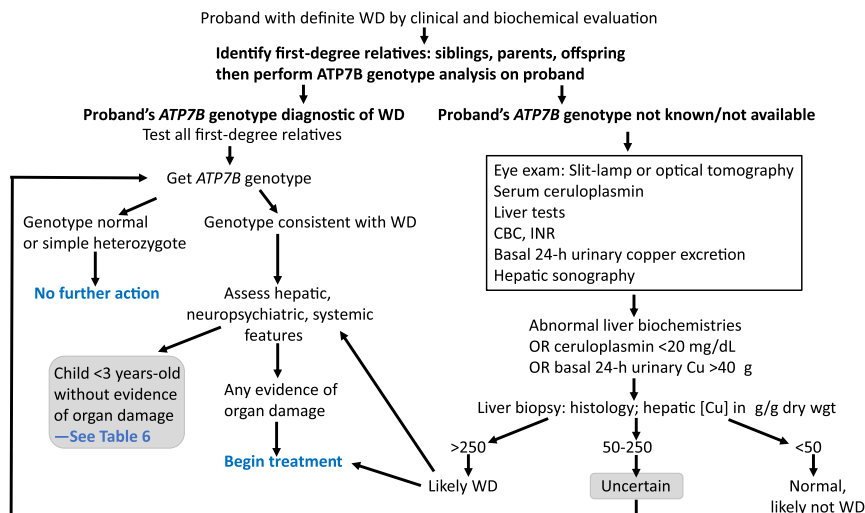
A broadly modified version of the Leipzig score has recently been developed as a diagnostic scoring system specifically for children.<sup>[246]</sup> Its rationale is the need to avoid delayed diagnosis when there are difficulties getting *ATP7B* genotyping and/or liver parenchymal copper measurement. Histochemical assessment for hepatic parenchymal and a “triad” of biochemical parameters are substituted. This reworked “pediatric” Leipzig score looked effective, but further validation is required.

### Diagnosis of ALF due to WD using standard clinical biochemistry data

The approach of Korman et al.<sup>[145]</sup> establishes a diagnosis of ALF due to WD using standard biochemistries (discussed previously). The combination of ratios (alkaline phosphatase to total bilirubin <4 and AST to ALT >2.2) is highly predictive in adults. A small pediatric study from France relied mainly on bilirubin and alkaline phosphatase.<sup>[247]</sup>

### Prognostic scoring systems

Prognostic scoring systems were developed and prospectively validated to predict when patients with WD would likely fail medical therapy. The Nazer score was the first, based on serum bilirubin, AST, and prothrombin time (PT).<sup>[248]</sup> A score ≥7 predicted death, whereas a score ≤6 predicted survival with chelation therapy.



**FIGURE 4** Screening for Wilson disease (WD) in first-degree relatives of an individual who has a secure diagnosis of WD (proband). The first step is to identify all first-degree relatives. If the proband's ATPase copper transporting beta (*ATP7B*) genotype is known, then genetic testing is the most efficient screening strategy. Otherwise, clinical testing is required. If clinical testing is inconclusive and genetic testing remains unavailable, then repeat noninvasive assessment (shown in box) should be performed at 6–12 months. Treatment trial may be considered. Genetic testing means analyzing *ATP7B* sequence to establish presence on each allele of a disease-associated mutation. CBC, complete blood count; Cu, copper; INR, international normalized ratio.

### New Wilson Index (NWI)

Experience with the Nazer score suggested that it was unreliable around the breakpoint (at 6–7). A new score was developed based on pediatric WD cases.<sup>[164]</sup> This score, the NWI, differs from the Nazer score by including the white blood cell count, serum albumin, and INR (not PT). Thus, it features surrogate markers of systemic inflammatory response syndrome and chronicity of liver disease. An NWI score of  $\geq 11$  was a strong predictor of mortality without liver transplantation (Table 8). The NWI was validated in adults.<sup>[249]</sup> The Model of End-stage Liver Disease (MELD), the Nazer score, and the NWI were compared by receiver-operator curve analysis. The area under the receiver operating characteristic curve was similar for the three scores, with the NWI marginally best. The NWI improves on the Nazer score and differs from MELD in being devised specifically for WD.

The challenge with both the Nazer score and the NWI is interpreting scores close to the breakpoint (NWI: 10–11) between need or no need for liver transplantation. Patients who present with severe decompensated chronic liver disease, including an acute-on-chronic liver failure pattern, and those with severe ALI without hepatic encephalopathy may be particularly problematic. Experience in such pediatric patients has suggested that the NWI scores can be unreliable.<sup>[250]</sup> With patients hovering around the breakpoint, trends of the NWI score on regular repeated evaluation may be highly informative.

### Other scoring systems

Other prognostic scoring systems have recently been developed and applied to decompensated chronic liver disease or ALF in children with WD. The Devarbavi

score was derived by multivariate logistical regression analysis and utilizes hepatic encephalopathy and serum bilirubin as key variables.<sup>[251]</sup> The Alam score applies the APASL ACLF Research Consortium-Acute on Chronic Liver Failure (AARC-ACLF) score to pediatric patients and appears highly informative.<sup>[238,252]</sup> These scoring systems require broader investigation in a variety of clinical contexts for WD.

### Guidance statements 12–13

12. Diagnostic scoring systems may aid clinicians in establishing or refuting a diagnosis of WD in patients not meeting classic descriptions of the disease and are also useful for purposes of research studies on WD.
13. Prognostic scoring systems may help in determining the potential for successful medical therapy for WD. Applying such a score serially over time may be critical to improve accuracy.

## SCREENING FOR WD

### Family screening

First-degree relatives of patients newly diagnosed with WD, even those who are asymptomatic, must be

**TABLE 7** Leipzig score for diagnosis of Wilson disease (with commentary)

Parameters	Points
<b>Specific clinical features</b>	
Kayser–Fleischer rings (by slit-lamp examination)	
Present	2
Absent	0
Neuropsychiatric symptoms suggestive of WD (or typical features on brain MRI <sup>a</sup> )	
Present	2
Absent	0
Coombs-negative (nonimmune) hemolytic anemia (plus high serum copper)	
Present	1
Absent	0
<b>Laboratory tests</b>	
24-h urinary copper excretion (in the absence of acute hepatitis)—ULN modified <sup>b</sup>	
Normal	0
1–2× ULN	1
> 2× ULN	2
Normal but >500 µg/day 1 day after challenge with 2× 500 mg D-penicillamine (see note <sup>c</sup> )	2
Liver copper quantitative <sup>d</sup>	
Normal (ULN = 50 µg/g dry weight)	–1
Up to 5× ULN	1
> 5× ULN	2
Rhodanine-positive hepatocytes (only if quantitative copper measurement not available)	
Absent	0
Present	1
Serum ceruloplasmin (nephelometric assay, LLN = 20 mg/dl <sup>e</sup> )	
Normal	0
10–20	1
< 10	2
<b>Mutation analysis (ATP7B)</b>	
Disease-causing mutations on both chromosomes	4
Disease-causing mutation on one chromosome	1
No disease-causing mutation detected	0
<b>Total score (not available: scores 0)</b>	
<b>Assessment of the WD-diagnosis score<sup>f</sup></b>	
4 or more: Diagnosis of Wilson disease highly likely	
2–3: Diagnosis of Wilson disease probable, do more investigations	
0–1: Diagnosis of Wilson disease unlikely	

Abbreviations: *ATP7B*, ATPase copper transporting beta (gene associated with WD); EEG, electroencephalogram; LLN, lower limit of normal; MRI, magnetic resonance imaging; ULN, upper limit of normal; WD, Wilson disease.

<sup>a</sup> Detailed MRI or EEG studies are only needed if neurological symptoms cannot be excluded with certainty by clinical neurological examination.

<sup>b</sup> ULN for children was subsequently modified to 40 µg/d; accruing experience indicates that this ULN is appropriate for adults.

<sup>c</sup> This criterion is likely not stringent enough; diagnostic threshold in original publication was >1600 µg/24-h.

<sup>d</sup> Liver biopsy is not mandatory for diagnosis and evaluation of patients with exclusively neurological findings. Histopathological assessment of liver was considered to be important for research protocols.

<sup>e</sup> Other values may apply when ceruloplasmin is measured by oxidase assay (generally not available in routine clinical laboratories).

<sup>f</sup> Certain disorders can reach “diagnostic” score values; see section on clinical mimics and Table 5.

Source: Adapted from Roberts<sup>[436]</sup> and based on Ferenci et al.<sup>[117]</sup>

screened for WD. If disease-specific mutations are identified in the proband, molecular testing for *ATP7B* mutations should be obtained and may be used as primary screening. Alternatively or in concert with

genetic testing, clinical and biochemical assessment should include a brief history relating to jaundice, liver disease, and subtle features of neurological or psychiatric involvement; physical examination; serum copper,



**TABLE 8** NWI prognostic scoring system for WD in conventional units

Points assigned	0	1	2	3	4
Bilirubin, mg/dl (μmol/L)	0–5.8 (0–100)	5.9–8.7 (101–150)	8.8–11.7 (151–200)	11.8–17.5 (201–300)	> 17.5 (> 300)
INR	0–1.29	1.3–1.6	1.7–1.9	2.0–2.4	≥ 2.5
AST, IU/L	0–100	101–150	151–200	201–300	> 300
WBC (×10 <sup>6</sup> /ml)	0–6.7	6.8–8.3	8.4–10.3	10.4–15.3	≥ 15.4
Albumin, mg/dl	> 4.5	3.4–4.4	2.5–3.3	2.1–2.4	≤ 2.0

*Note:* Like the Nazer index, the NWI<sup>[164]</sup> assigns points to serum [total] bilirubin, AST, and coagulation capacity (here: INR; previously in Nazer score: prothrombin time). In contrast, the NWI also assigns points also to WBC and serum albumin. Values here have been converted from SI to conventional units (bilirubin in SI units, provided in parentheses). The points assigned for each of the five parameters are summed to generate the score. A score of ≥ 11 is a strong predictor of mortality without liver transplantation. On receiver-operator curve analysis in adults,<sup>[437]</sup> the NWI performed better than the Nazer score and Model of End-stage Liver Disease. Abbreviations: AST, aspartate aminotransferase; INR, international normalized ratio; NWI, New Wilson Index; WBC, white blood cell count; WD, Wilson disease.

ceruloplasmin, and biochemical liver tests including aminotransferases, albumin, and conjugated and unconjugated bilirubin; slit-lamp examination of the eyes for KF rings; and basal 24-h urinary copper excretion (Figure 4). Individuals without KF rings who have subnormal ceruloplasmin and abnormal liver tests should undergo liver biopsy to confirm the diagnosis.

## Newborn screening

Although WD is suitable for newborn screening, no testing strategy has yet been established. Measurement of ceruloplasmin in dried blood spots or urine samples from newborns was investigated, but methodology requires further refinement.<sup>[253–255]</sup> A proteomic approach for quantifying ATP7B peptides in dried blood spots is in development.<sup>[256]</sup>

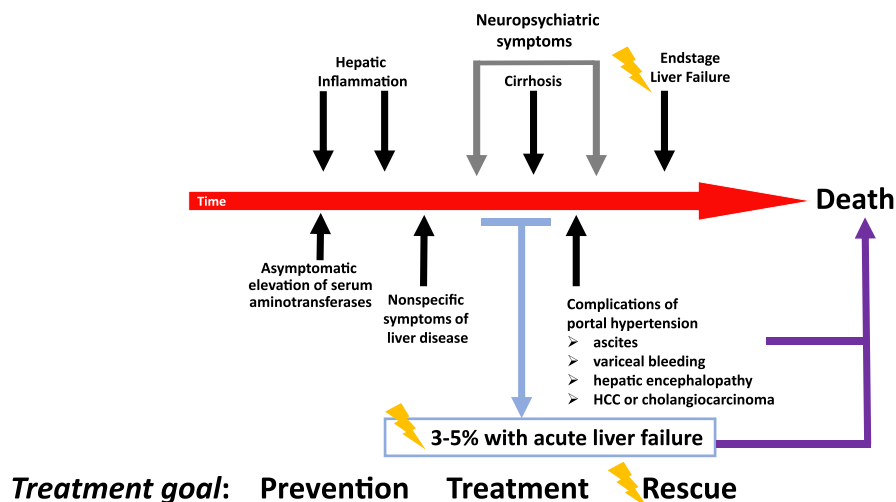
Prenatal testing based on genotype analysis can be performed.<sup>[257,258]</sup> Diagnosis in the neonatal period also permits timely treatment.<sup>[259,260]</sup>

### Guidance statement 14

14. First-degree relatives of patients newly diagnosed with WD must be screened for WD. Within a pedigree where there is one or more individuals with WD, any person with signs or symptoms consistent with WD, irrespective of closeness of relationship, should be evaluated for WD. Available strategies are genotype assessment of *ATP7B* and comprehensive clinical evaluation (summarized in Figure 4).

**TABLE 9** Currently available oral treatments for Wilson disease

Drug	Mode of action	Neurological worsening	Side effects	Comments
D-Penicillamine	General chelator induces renal excretion of copper	10%–20% during initial phase of treatment	<ul style="list-style-type: none"> <li>• Fever, rash, proteinuria, lupus-like reaction</li> <li>• Aplastic anemia</li> <li>• Leukopenia</li> <li>• Thrombocytopenia</li> <li>• Nephrotic syndrome</li> <li>• Degenerative changes in skin</li> <li>• Elastosis perforans serpiginosa</li> <li>• Serous retinitis</li> <li>• Hepatotoxicity</li> <li>• Colitis</li> </ul>	Reduce dose for surgery to promote wound-healing and during pregnancy
Trientine	General chelator induces renal excretion of copper	10%–15% during initial phase of treatment	<ul style="list-style-type: none"> <li>• Gastritis</li> <li>• Aplastic anemia rare</li> <li>• Sideroblastic anemia</li> <li>• Colitis</li> </ul>	Reduce dose for surgery to promote wound-healing and during pregnancy
Zinc	Metallothionein inducer, blocks intestinal copper absorption	Can occur during initial phase of treatment	<ul style="list-style-type: none"> <li>• Gastritis</li> <li>• Biochemical pancreatitis</li> <li>• Zinc accumulation</li> <li>• Possible changes in immune function</li> </ul>	No dosage reduction for surgery or pregnancy



**FIGURE 5** Customizing Wilson disease (WD) treatment to the character of clinical disease: treatment goals with respect to the liver are dependent on phase of disease. With effective treatment started early and taken consistently, WD survival approximates to the normal survival of the population. “Rescue” options directed at WD include an intensive medical treatment protocol with temporally dispersed combination of chelator and zinc, and liver transplantation. HCC, hepatocellular carcinoma.

## TREATMENT

For nearly half a century following the description of “lenticular degeneration” by Wilson in 1912, there were no effective treatments for this progressively fatal disorder. Penicillamine, as a racemic mixture, was introduced in the mid-1950s. Observational studies attested to its efficacy; D-penicillamine was associated with fewer adverse effects. Advances in diagnostic testing for WD permitted recognition that significant morbidity and mortality could be prevented by treating asymptomatic patients with WD.<sup>[261]</sup> Intolerance to D-penicillamine in some patients with WD stimulated development of alternative agents, notably trientine. Zinc was developed separately, as was the oral chelator tetrathiomolybdate (TTM). Today, the mainstay of treatment for WD remains lifelong oral pharmacotherapy (Table 9) and dietary copper restriction. Oral chelators require adequate renal function to be effective. Liver transplantation, which corrects the underlying hepatic defect in WD, is reserved for severe cases and those resistant to pharmacotherapy.

The goals of WD treatment depend upon the phase of disease (Figure 5) and must consider both drug safety and efficacy in the individual patient. The approach to treatment initiation depends on whether the patient is symptomatic or not and whether organ damage is present. Symptomatic patients have clinically evident disease, which is usually hepatic or neuropsychiatric but may involve other organ systems. Asymptomatic individuals with WD have no clinical symptoms at all. Some have no evidence of organ damage. Others who are asymptomatic have biochemical, histological, or imaging evidence of organ damage. Asymptomatic WD is often identified simply on the basis of family screening, sometimes by genotype alone. Distinguishing symptomatic and asymptomatic individuals with

evidence of organ damage (asymptomatic active disease) from those asymptomatic individuals who have no organ damage helps in determining the choice and dosage of medications for primary treatment of WD, although studies systematically exploring this approach are lacking. Recommended initial treatment of symptomatic or asymptomatic patients with active disease is with chelating agents, though zinc may be adequate for some.

Along with primary treatment of WD, patients with advanced liver disease must be treated for any complications of portal hypertension. Elastography may be informative in hepatic WD,<sup>[262]</sup> but its role is evolving. Patients with WD who manifest neurological or psychiatric symptoms may benefit from treatments directed at those symptoms along with WD therapy. Patients with WD require immunization against hepatitis A and B, unless already immune to these viruses. They should have immunizations directed against potentially life-threatening intercurrent infections (such as varicella, COVID-19, pneumococcal). They should maintain general good health, including normal body weight and cardiovascular fitness.

Disease symptoms and biochemical abnormalities stabilize in most patients within 6–18 months after initiation of consistent therapy.<sup>[263]</sup> Reduced dosages of chelators or zinc can then be used for maintenance therapy. Asymptomatic patients without evidence of organ damage may be treated initially with either the lower maintenance dosages of a chelating agent or with zinc. Failure to comply with lifelong therapy typically leads to recurrent or new symptoms and liver failure, the latter requiring liver transplantation for survival. Monitoring of therapy includes clinical examination and biochemical testing to demonstrate clinical improvement or stability, depending on whether the patient was

symptomatic or not at the start of treatment. Checking adherence and treatment-induced adverse effects regularly is important to achieve best outcomes.

## Treatments and therapeutic targets

The following is pharmacotherapy utilized for WD. These oral agents were developed originally for treatment of symptomatic WD, but their role has evolved to include asymptomatic patients and long-term maintenance therapy. Local variations in drug availability and cost may influence choice of treatment.

Certain general principles apply to all WD pharmacotherapy. Asymptomatic patients should remain asymptomatic on treatment. For patients with symptomatic liver disease, improvement in synthetic function and clinical signs such as jaundice and ascites begins during the first 2–6 months of treatment, with further recovery possible over time. Failure to adhere to therapy has led to progression of liver disease and liver failure in 1–12 months following treatment discontinuation, resulting in death or liver transplantation.<sup>[264]</sup>

### D-Penicillamine

Penicillamine was the first oral treatment for WD.<sup>[265]</sup> It is a dimethylated version of the amino acid cysteine which has a free sulfhydryl group that functions as the copper chelating moiety. The isomer D-penicillamine is preferred because of better tolerability. The effect of D-penicillamine that is important in WD is to promote urinary copper excretion. After starting on D-penicillamine, 24-h urinary copper excretion often is >1000 µg/day, decreasing over time as total-body copper stores diminish. It may also act by inducing metallothionein.<sup>[266]</sup>

D-Penicillamine is rapidly absorbed from the gastrointestinal tract with a double-peaked curve for intestinal absorption.<sup>[267–269]</sup> Uptake may occur by disulfide binding to the enterocyte membrane followed by pinocytosis. If D-penicillamine is taken with a meal, its absorption is decreased overall by approximately 50%.<sup>[269,270]</sup> Total bioavailability is estimated at 40%–70%.<sup>[268,271]</sup> Once absorbed, 80% of D-penicillamine circulates bound to plasma proteins; there is little free D-penicillamine because it forms inactive dimers or binds to cysteine. Most (>80%) of D-penicillamine excretion is renal. The excretion half-life of D-penicillamine shows considerable interindividual variation, ranging approximately 1.7–7 h.<sup>[267,269,271]</sup> Early observations suggested that D-penicillamine or its metabolites can be found in the urine months after the drug has been discontinued<sup>[272]</sup>; however, more recent data indicate that most of the D-penicillamine-induced urinary copper excretion is no longer apparent after 48 h.

Initially D-penicillamine in WD was used for treatment of symptomatic patients, and numerous studies demonstrated effectiveness.<sup>[136,273–278]</sup> A severe or “paradoxical” worsening of neurological symptoms was reported in 10%–50% during the initial phase of treatment with D-penicillamine.<sup>[279]</sup> In a subsequent series, neurological worsening occurred with D-penicillamine, trientine, and zinc, but mainly with D-penicillamine, where 13.8% were adversely affected.<sup>[74]</sup> Litwin et al.<sup>[280]</sup> reported that neurological worsening tended to occur most often in those with neurological signs and symptoms of disease.

D-Penicillamine use is associated with numerous adverse effects. Severe adverse effects requiring drug discontinuation occur in approximately 30%.<sup>[73,135]</sup> Early sensitivity reactions marked by fever and cutaneous eruptions, lymphadenopathy, neutropenia or thrombocytopenia, and proteinuria may occur during the first 1–3 weeks. D-Penicillamine should be discontinued immediately if early sensitivity occurs; availability of alternative medications makes a trial of prednisone for desensitization unnecessary. Later reactions including nephrotoxicity, indicated by proteinuria or appearance of cellular elements in the urine, should prompt immediate discontinuation of D-penicillamine. Bone marrow toxicity includes severe thrombocytopenia or total aplasia that may be irreversible despite discontinuation of therapy. Dermatological toxicities include progeric changes in the skin and elastosis perforans serpiginosa,<sup>[281]</sup> pemphigus or pemphigoid lesions, lichen planus, and aphthous stomatitis. Other reported late reactions include a lupus-like syndrome marked by hematuria, proteinuria, and positive antinuclear antibody. Goodpasture syndrome occurred with higher dosages of D-penicillamine that are no longer typically used for treating WD. Very late adverse effects include nephrotoxicity, severe allergic response upon restarting the drug after prior discontinuation, myasthenia gravis, polymyositis, loss of taste, immunoglobulin A depression, and serous retinitis. Hepatotoxicity has been reported.<sup>[282]</sup> Hepatic siderosis was reported in over-treated patients with associated reduced levels of serum ceruloplasmin and NCC.<sup>[283]</sup>

Incremental dosing may enhance tolerability of D-penicillamine, starting with 250–500 mg/day and then increasing by 250-mg increments every 4–7 days to approximately 1000–1500 mg/day (15–20 mg/kg/day to a maximum of 2000 mg/day) in 2–4 divided doses. This “start low and go slow” approach is strongly recommended by some experts to avoid neurological worsening, but no controlled studies are available. Maintenance dose in adults is 10–15 mg/kg/day (approximately 750–1000 mg/day) administered in two divided doses. Dosing in children is 20 mg/kg/day rounded off to the nearest 250 mg, given in two or three divided doses, started incrementally; the dose may be reduced to 10–15 mg/kg for maintenance over time. For best pharmacological effect, D-penicillamine

should be administered 1 h prior to or 2 h after meals because food inhibits its absorption. Closer proximity to meals may be acceptable if it ensures adherence; however, effectiveness of treatment then needs to be closely monitored. Pyridoxine (25–50 mg by mouth daily) is routinely administered to patients on D-penicillamine, although interference with pyridoxine action is rarely encountered because the racemic mixture of D,L-penicillamine is no longer in use.

### **Treatment targets**

Adequacy of treatment is monitored by clinical and biochemical improvement and by measuring 24-h urinary copper excretion on treatment. This is highest immediately after starting treatment, when it may exceed 1000–2000  $\mu\text{g}/24\text{ h}$ . With chronic (maintenance) treatment, urinary copper excretion should be approximately 200–500  $\mu\text{g}/24\text{ h}$  (3–8  $\mu\text{mol}/24\text{ h}$ ).<sup>[134]</sup> Serum NCC shows normalization with effective treatment. Values of 24-h urinary copper excretion  $>500\text{ }\mu\text{g}/24\text{ h}$  in treated patients previously excreting 200–500  $\mu\text{g}/24\text{ h}$  suggest nonadherence to medication or excessive liberalization of dietary copper. It can also be due to poor drug absorption, inadvertently low dosing, or ALI. Urinary copper excretion  $<100\text{ }\mu\text{g}/24\text{ h}$  may signal overtreatment resulting from excessive copper removal or, occasionally, nonadherence if treatment interruption was recent. With overtreatment, serum copper and CuEXC are very low, as is the NCC (typically  $<5\text{ }\mu\text{g}/\text{dl}$ ), although the estimated NCC may not accurately reflect this. In those nonadherent to D-penicillamine therapy, serum copper and CuEXC are elevated, and NCC may be elevated ( $>25\text{ }\mu\text{g}/\text{dl}$ ).

With D-penicillamine treatment, serum ceruloplasmin may also decrease and remain low or increase over the term of chronic treatment, the latter occurring in those with severe hepatic insufficiency who recover synthetic function in response to treatment. In contrast, a decrease in serum ceruloplasmin in chronically treated patients may indicate overtreatment and is often associated with neutropenia, sideroblastic anemia, and hemosiderosis.

## **Trientine**

Trientine (triethylenetetramine dihydrochloride; 2,2,2-tetramine or “trien”; also available as triethylenetetramine tetrahydrochloride) has a polyamine-like structure that is chemically distinct from penicillamine. Specifically, it lacks sulfhydryl groups. Copper is chelated by forming a stable complex with the four constituent nitrogens in a planar ring.

Trientine was introduced in 1969 as an alternative to D-penicillamine. Like D-penicillamine, the primary action of trientine is promotion of renal copper excretion.

Urinary copper excretion typically is  $>1000\text{ }\mu\text{g}$  copper per day with treatment initiation: it decreases over time as total-body copper stores diminish. Additionally, administered with food in healthy subjects, trientine blocks dietary copper absorption.<sup>[284]</sup> There are limited data on the pharmacokinetics of trientine. Trientine is poorly absorbed from the gastrointestinal tract; much of what is absorbed is metabolized and inactivated. The median  $t_{1/2}$  for absorption is approximately 1.5 h in patients with WD.<sup>[285]</sup> Only approximately 1% of the administered trientine and approximately 8% of the biotransformed trientine metabolite, acetyltrien, ultimately appear in urine. Acetyltrien is a less effective chelator than trientine. Biotransformation of trientine is probably through phase II conjugation pathways for polyamines, which trientine resembles structurally.<sup>[284]</sup> These acetylation pathways are separate from N-acetyltransferase 1 (NAT1) and N-acyltransferase 2 (NAT2). The excretion  $t_{1/2}$  is approximately 3 h. Recent studies suggest the pharmacokinetics for trientine dihydrochloride is similar in normal controls and in patients with WD, notably both adult and pediatric patients.<sup>[285]</sup>

Trientine, like D-penicillamine, may bind metals other than copper. Along with copper, zinc and iron in urine increase in parallel with the amount of excreted trientine.<sup>[286]</sup> Whether trientine is a weaker chelator of copper than D-penicillamine is controversial<sup>[274,287,288]</sup>; however, dose adjustments can compensate for small differences in induced cupriuresis between the two medications. Trientine and D-penicillamine may mobilize different pools of body copper.<sup>[287]</sup>

Trientine is effective treatment for WD<sup>[264,289]</sup> and is indicated especially in patients who are intolerant of D-penicillamine. It may be preferable for patients with WD who have severe thrombocytopenia or neutropenia that can occur with splenomegaly. Paradoxical neurological worsening after beginning treatment with trientine appears to be less common than with D-penicillamine, although head-to-head comparison was never performed. Trientine was effective initial therapy for patients, even with decompensated liver disease at the outset.<sup>[290,291]</sup> Available data suggest that trientine is safe and effective in pediatric patients with WD.<sup>[292,293]</sup>

The tetrahydrochloride form of trientine was approved in 2022 by the Food and Drug Administration (FDA) for previously treated D-penicillamine-tolerant patients with WD. Bioequivalence between trientine dihydrochloride and trientine tetrahydrochloride has not yet been established because of differences in pharmacokinetics and bioavailability. Initiating trientine tetrahydrochloride may require individual dose adjustments, which may be based on 24-h urinary copper excretion, in order to maintain clinical and biochemical stability. Other biochemical parameters to guide effective dosing of trientine tetrahydrochloride are being developed.



Trientine has few side effects. No hypersensitivity reactions have been reported, although a fixed drug reaction was observed in one patient. Pancytopenia has rarely been reported. Colitis can develop in rare patients on trientine, as with D-penicillamine.<sup>[294]</sup> Trientine also chelates iron. Coadministration of trientine and iron should be avoided because the complex with iron is toxic. Lupus-like reactions were reported in some patients with WD treated with trientine; however, these patients were almost all treated previously with D-penicillamine, so the true frequency of this reaction for trientine as initial treatment is unknown. Accumulated clinical experience suggests that adverse effects due to D-penicillamine resolve when trientine is substituted for D-penicillamine and do not recur. In patients with primary biliary cholangitis, trientine was reported to cause hemorrhagic gastritis, loss of taste, and rashes.<sup>[295]</sup> Esophageal irritation can occur: trientine should be taken with ample fluid.

Typical adult dosage for initial treatment is approximately 15–20 mg/kg/day (to 2000 mg daily maximum) in two or three divided doses. As with D-penicillamine, the dose for initial therapy with trientine should be ramped up over several (2–3) weeks. The maintenance dose for adults is 10–15 mg/kg/day in two or three divided doses. In children, the initial dose generally used is 20 mg/kg/day rounded off to the nearest 250 mg, given in two or three divided doses, started incrementally. Exceeding 20 mg/kg/day may be associated with increased adverse effects.<sup>[293]</sup> Maintenance treatment in children can be 10–15 mg/kg/day, but normal growth often compensates for actual dose modification. Trientine should be administered 1 h before or 2 h after meals. The dihydrochloride formulation of trientine should be stored refrigerated to avoid oxidative degradation, which reduces the shelf-life of the medication. Newer packaging can improve ambient temperature stability for trientine dihydrochloride. The newly introduced tetrahydrochloride form of trientine is stable at ambient temperature. Once-daily dosing of trientine in clinically stable patients may be safe and enhance adherence, but it requires confirmatory studies.<sup>[296]</sup>

### **Treatment targets**

Adequacy of treatment is judged by clinical and biochemical improvement and subsequent stability and by measuring 24 h urinary copper excretion on treatment. Urinary copper excretion upon initiation of treatment is often >1000 µg/24 h and decreases over time on treatment to approximately 3–10 times the upper limit of normal for urinary copper excretion (typically approximately 150–500 µg/24 h).<sup>[297]</sup>

Generally, with nonadherence to therapy over time, urinary copper rises. In the context of chronic dosing, urinary copper excretion higher than treatment goal may reflect nonadherence, but it can also be due to other causes of insufficient drug action (poor drug absorption,

unintentionally low dosing) or intercurrent ALI. Values of urinary copper excretion <100 µg/24 h may indicate some degree of copper deficiency due to overtreatment resulting in excess copper removal. In such a situation, serum copper is expected to be lower than pretreatment values. Reversible sideroblastic anemia and neutropenia may be present. Overtreatment can result in hepatic iron overload in patients with WD, similar to that observed for D-penicillamine.<sup>[283]</sup> In contrast, when low urinary copper excretion accompanies nonadherence, serum copper increases, reflecting increased NCC.

### **Zinc (zinc salts)**

Zinc was first used to treat WD by Schouwink in the Netherlands in the early 1960s.<sup>[298,299]</sup> Its mechanism of action differs from that of D-penicillamine and trientine. Zinc inhibits the intestinal uptake of copper by inducing enterocyte metallothionein, an endogenous chelator with a greater affinity for copper than for zinc. Ingested copper taken up into the enterocytes binds to cytoplasmic metallothionein more avidly than zinc. The copper-metallothionein is excreted in the feces as enterocytes are shed in normal turnover.<sup>[300]</sup> Thus, the copper is not absorbed into the portal circulation. Because copper also enters the gastrointestinal tract from saliva and gastric secretions, zinc treatment generates a negative balance for copper and removes tissue copper, albeit relatively slowly.<sup>[301]</sup> Zinc may also improve hepatic resistance to copper toxicity by inducing hepatocellular metallothionein.<sup>[302]</sup> Zinc may reverse Cu-mediated interference with nuclear receptors and thus improve hepatocellular metabolism.<sup>[303]</sup>

Zinc has very few side effects. Gastric irritation or gastritis is the most common adverse effect, occurring in approximately one third of patients. It may be dependent on the type of zinc salt. In one survey, approximately 38% of patients changed the zinc salt used to treat their WD due to gastrointestinal symptoms.<sup>[304]</sup> Gastric irritation rarely is severe. In children, zinc sulfate may be problematic: in one pediatric case, gastric perforation occurred.<sup>[305,306]</sup> Changing to a different salt or taking zinc with a very small amount of protein may alleviate symptoms. Zinc treatment to block dietary copper absorption is effective in the majority of but not all patients with WD. In the initial studies by Brewer et al., some individuals failed to have adequate blockage of dietary copper.<sup>[307]</sup> Hepatic deterioration was occasionally reported in WD on zinc monotherapy and was fatal in one case<sup>[308–310]</sup>; however, it is unknown if these individuals were properly adherent to their therapy. Early paradoxical neurological deterioration is uncommon with zinc<sup>[278,300]</sup> but may occur.<sup>[310]</sup> Elevation in serum lipase or amylase may occur with zinc treatment for WD, without clinical or radiologic evidence of pancreatitis. Zinc may be utilized

in patients with impaired renal function when therapy with chelation requiring urinary copper excretion might be ineffective.

Although zinc is currently reserved for maintenance treatment of WD, it is used as first-line therapy, most commonly for asymptomatic patients. It appears to be equally effective as D-penicillamine but much better tolerated.<sup>[278,311]</sup> Reports of large series of adults with WD indicate good efficacy,<sup>[299,310,312,313]</sup> possibly better in those with neurologic WD. In children with mild or asymptomatic WD, zinc treatment as primary therapy appears to be effective,<sup>[314–316]</sup> although some express caution.<sup>[306]</sup> Some individuals with severe disease were reported as doing well on zinc monotherapy.<sup>[314,317]</sup> “Combination” treatment with trientine plus zinc or D-penicillamine plus zinc has been advocated as treatment for severe disease: each is given at widely spaced intervals during the day, never simultaneously (see detailed discussion under “Decompensated Cirrhosis”).

Dosing is in milligrams of *elemental* zinc. For larger children and adults, 150 mg/day is administered in three divided doses. It must be taken at least twice daily to be effective.<sup>[312]</sup> The actual salt used does not appear to make a difference with respect to efficacy as measured by the percent reaching goals for urinary copper excretion and normalization of serum ALT<sup>[304]</sup> but may affect individual tolerability. For smaller children <50 kg in body weight, the dose is 75 mg/day in three divided doses.<sup>[318]</sup> The dose is not well defined for children who are less than 5 years-old; however, 50 mg/day in two divided doses has been postulated,<sup>[318]</sup> similar to a weight-based dose.<sup>[319]</sup> Taking zinc with food interferes with zinc absorption<sup>[320]</sup> and treatment effectiveness.

### Treatment targets

Adequacy of treatment with zinc is judged by clinical and biochemical improvement and by measuring 24-h urinary excretion of copper, which should be <100 µg (<1.6 µmol)/24 h on stable treatment. ALT normalization may be a good marker of effective treatment and positively correlates with the maintenance of 24-h urinary copper excretion below this threshold of 100 µg/24 h.<sup>[304,310]</sup> Additionally, elevated NCC normalizes with effective treatment; the estimated NCC may indicate this normalization.

Zinc lacks efficacy in a subset of patients with WD, but it is impossible to identify these patients prospectively. Failure of zinc therapy in those in whom it was initially effective is most often associated with non-adherence, missing doses, or poor absorption due to taking it with food. Rarely, it may be due to underdosing if the childhood dose is not adjusted upward as children grow up. Overtreatment with zinc is suspected when urinary copper excretion is very low (<20 µg [<0.3 µmol]/24 h), associated with low serum copper and lower ceruloplasmin concentration. It necessitates

a reduction in a patient's daily zinc dose or even a brief interruption of therapy if other hematologic or neurological side effects are present. These include development of a sideroblastic anemia with leukopenia or neutropenia or neurological deficits such as ataxia or peripheral neuropathy. Neurological changes from zinc therapy for WD are uncommon and develop when copper depletion is severe and prolonged, usually after 5–15 years or more of treatment.<sup>[321]</sup>

Adherence to treatment over the long term is an important issue with zinc treatment for WD. The three-times-daily dosage regimen stipulated to be strictly away from meals can prove problematic for some people, for example, adolescents and young adults. Zinc appeared more efficacious in neurologic WD than in hepatic WD, where more treatment failures occurred; however, the contribution of poor adherence to these findings could not be excluded.<sup>[310]</sup> Clinical monitoring needs to be stringent. Rise in serum aminotransferases may be an early sign of poor adherence or of treatment failure. Increased 24-h urinary copper excretion suggests poor adherence or increased dietary copper intake. Urinary excretion of zinc, with target values of >1–2 mg/24 h, may be measured from time to time to check adherence.<sup>[312]</sup> The amount of urinary zinc correlates positively with the total daily dosage of zinc a patient is taking.<sup>[304]</sup> Serum zinc levels may be informative and should be >125 µg/dl.<sup>[312]</sup>

### Tetrathiomolybdate (TTM)

TTM is an orally administered chelating agent, proposed to work by multiple mechanisms.<sup>[322]</sup> In the circulation, TTM creates a nonreactive tripartite complex with albumin and copper. TTM may also promote biliary excretion of copper. TTM has a high binding constant and can remove copper bound to metallothionein.<sup>[323]</sup> When TTM is administered with food, it interferes with the intestinal uptake of copper. The first formulation investigated for treating WD was the less stable, easily oxidized ammonium salt. TTM as the more stable bis-choline salt is in late stages of drug development and is not yet commercially available. Data from phase II suggested that TTM caused an effective reduction in NCC (corrected for Cu-TTM-albumin complex) and an improvement in clinical neurological symptoms, without paradoxical neurological worsening as demonstrated by an overall improvement in their UWDRS scores.<sup>[324]</sup> Early elevation of serum aminotransferases in approximately 30% resolved with dose discontinuation or reduction; none developed evidence of drug-induced liver injury. Suitability for treating advanced hepatic WD requires further investigation. As seen in prior trials of ammonium-TTM, patients can develop neutropenia, which was also reversible when the drug was discontinued or the

dosage reduced. Results of a phase III trial of bis-choline TTM for WD are expected in the near future.

## Antioxidants

Antioxidants, mainly vitamin E, have been proposed as adjunctive treatment. The rationale was that serum and hepatic vitamin E levels were low in WD.<sup>[325–327]</sup> Other antioxidants of potential benefit include vitamin C, *N*-acetylcysteine, and curcumin.

One study in WD suggested no correlation of antioxidant deficiency with clinical symptoms.<sup>[328]</sup> A more recent study showed that biochemical evidence of oxidative stress was higher in neurologic WD than in hepatic WD and correlated with severity of symptoms.<sup>[329]</sup> Similar findings, including decreased serum glutathione, were reported in a smaller study of patients with neurologic WD.<sup>[330]</sup> Evidence for oxidative stress, worse with more severe liver damage, was demonstrated in children with hepatic WD.<sup>[331]</sup> Symptomatic improvement when vitamin E was added to the treatment regimen was occasionally reported, but data for hepatic WD are mainly anecdotal because no rigorous studies have been conducted. One study in which vitamin E and vitamin C were added to treatment with chelator and/or zinc showed clinical improvement in neurologic WD in the group receiving antioxidants,<sup>[332]</sup> with the caveat that the two groups were comparable but treatment was not randomized.

## Asymptomatic patients

Asymptomatic patients require treatment; however, urgency for starting treatment is greater if there is any evidence of organ damage due to either inflammation or structural damage. Treatment with a chelating agent, such as D-penicillamine<sup>[261,333]</sup> or trientine, or with zinc<sup>[334]</sup> effectively prevents disease progression and symptomatic disease. The starting dose of medication may be the same as for maintenance dosing. Individualization is important in children who are less than 3 years-old. Zinc appears preferable for these very young asymptomatic children, but there is no consensus as to whether treatment should be started without evidence of organ damage because of possible adverse effects of treatment on development.<sup>[260]</sup>

## Maintenance therapy

After adequate treatment with a chelator, stable patients may continue on a lower dosage of drug (as noted above), or treatment may be changed to zinc. Adequate studies regarding the timing of this change in treatment of adult patients with hepatic WD are not available, and only limited data are available for children.<sup>[335]</sup> Thus, strict

criteria for eligibility for maintenance therapy cannot be specified; however, several general principles may apply. Typically, patients will have been treated for 1–5 years, but some will be suitable after only 6–12 months of treatment. They will be clinically well, with normal (or near-normal and improving) serum aminotransferase levels and hepatic synthetic function and with 24-h urinary copper excretion repeatedly in the therapeutic range on chelation treatment. Transitioning to maintenance therapy entails clinical and biochemical monitoring in the first 2–6 months (as opposed to standard 6-month intervals) to ensure effective therapy. Chelation therapy has a long track record of success as maintenance therapy, but adverse effects do cause discontinuation in a minority, more often with D-penicillamine. Long-term maintenance treatment with zinc is associated with few side effects, except for gastric intolerance. However, zinc requires multiple daily doses to be effective. Whichever therapy is chosen, regular follow-up should be continued because adherence remains an issue in many patients and late failures sometimes occur.

### Guidance statements 15–18

15. All patients with a newly established diagnosis of WD should be initiated on lifelong medical therapy for WD. Timing of treatment in children who are less than 3 years-old should be individualized to the degree of organ damage.
16. Initial treatment for symptomatic patients with WD should include a chelating agent (D-penicillamine or trientine). Trientine may be better tolerated.
17. Treatment of asymptomatic patients with WD can be a chelating agent (D-penicillamine or trientine at a lower dose than for initial therapy) or zinc.
18. The suitability for transition to maintenance therapy for WD includes time on therapy (generally more than 1 year) and favorable clinical and biochemical response to therapy. Maintenance therapy may be a lower dose of chelating agent (D-penicillamine or trientine) or full-dose zinc.

## NUTRITION

The average diet is replete with copper and serves as the source of copper for replenishing normal losses of this trace element. The recommended dietary

allowance (RDA) for copper for healthy adults is 0.9 mg/day. The median copper intake from foods in the United States is 1–1.6 mg/day according to the US National Health and Nutrition Examination Survey.<sup>[336]</sup> Although there is no firm consensus on how strictly dietary copper should be limited in WD,<sup>[337,338]</sup> WD cannot be treated exclusively by dietary measures.<sup>[339]</sup>

A few foods with very high concentrations of copper (nuts, chocolate, most shellfish, soy-based products, mushrooms, organ meats) should be avoided, at least in the first year of treatment. Health foods and supplements should be scrutinized for copper content.<sup>[340]</sup> Maintaining a well-balanced diet and healthy body weight is important. Individualizing diet is often required and beneficial for allaying fears about foods or overly restrictive diets. Many patients with WD benefit from working with a registered dietitian (RD), notably those who are vegetarians or vegans or who have food allergies or gastrointestinal disorders, such as irritable bowel syndrome. Infants and young children with WD have special dietary needs.

## Adults and adolescents with WD

Past guidance has traditionally advised a limited daily copper intake for patients with WD; however, few evidence-based data support a copper-restricted diet.<sup>[338]</sup> A moderated copper intake complements medical therapy. RDs can facilitate implementation of a workable and effective personalized dietary plan. Diet has the greatest potential impact on medical management during the initial treatment phase, especially in symptomatic patients. Patients with WD should try to keep intake of copper to the RDA, <0.9 mg/day. In addition to a few foods with very high concentrations of copper (nuts, chocolate, most shellfish, soy-based products, mushrooms, organ meats), most nondairy milk alternatives should be avoided, as they have high copper content. Among shellfish, scallops are quite low in copper. Vegetable-derived “meat” products, such as meatless burgers, are also high in copper, because most are soy- or legume-based. During the maintenance phase of disease management, individuals should continue to be mindful of copper intake, with emphasis on low-copper (<0.08 mg copper/serving) and moderate-copper (0.08–0.2 mg copper/serving) foods making up the base of their diet, though no specific limitation per day is recommended (Appendix S1). Serving size needs to be considered when determining copper load. Supervision by an RD can also help patients who find copper-related dietary restrictions problematic and may be helpful to patients with WD who adopt restrictive diets for any reason.

## Infants with WD, aged 0–6 months

There is no RDA for copper intake for infants, and likewise there are no set intake values in particular for infants with WD who still need copper for postnatal development. An adequate intake (AI) level of 0.2 mg/day is set for infants, reflecting the observed mean copper intake of infants fed principally human milk.<sup>[336]</sup> Young infants with WD should receive breastmilk or standard formula to meet these needs. Breastmilk copper content is highest in early lactation and decreases over time, on average providing 0.36 mg/L copper.<sup>[341]</sup> Intake of breastmilk in the first year of life can range anywhere from 480–1020 ml/day (16–34 oz/day), bringing copper intake to 0.19–0.41 mg/day, which is 96%–204% of the AI.<sup>[260]</sup> If breastmilk is not an option, infant formulas provide an appropriate alternative with average copper content ranging slightly higher than breastmilk at 0.4–0.6 mg/L, thus bringing average copper intake to 0.18–0.57 mg/day on standard formula (90%–285% of the AI) (Appendix S2). Partially and fully hydrolyzed formulas run slightly higher still but may be necessary based on gastrointestinal tolerance.<sup>[260]</sup> Breastmilk and infant formulas also provide fairly high concentrations of zinc.<sup>[260]</sup> Both copper and zinc are required for early postnatal development. In the uncommon situation of an affected infant born to a mother who has WD, the infant still requires some copper but needs close monitoring; anxiety over potential adverse effects of medication secreted into breastmilk may tip the choice toward infant formula. Likewise, choosing how to feed an unaffected infant born to a mother with WD must also take into account the potential adverse effects of WD medication secreted into breastmilk (see “Pregnancy”).

## Children with WD, aged 6 months and older

Once solid food is introduced (at approximately 5–6 months of age), copper intake can vary widely depending on food choices. The RDA for copper for children 1–3 years-old is 0.34 mg/day, 4–8 years-old is 0.44 mg/day, and 9–13 years-old is 0.7 mg/day. Children 14–18 years-old approximate the adult value. Cow's milk provides a significant portion of calories for young children who are more than 1 year-old and is a low-copper choice at 0.06–0.09 mg/L. Some parents may choose or need to use a nondairy milk alternative because of a diagnosed allergy. Nondairy milk alternatives are typically much higher in copper content than cow's milk (almond: approximately three times as much copper as dairy milk; rice: approximately four times as much; soy: approximately 19 times as much; coconut: approximately 20 times as much; pea: unknown, likely to be high). The nutritional content of these alternative milks can also vary significantly. If a milk alternative is desired or required, individuals should work with an RD to make nutritionally sound choices.



An overly restrictive solid food diet based on copper content is likely inadvisable. A wide variety of foods should be introduced as recommended by the child's pediatrician, though emphasis on low- and moderate-copper choices is prudent. Homemade baby foods made from liver as part of a baby-led weaning strategy should be avoided.

## Household considerations

### Water

Copper content of drinking water can vary from  $<0.005$  mg/L to as high as 30 mg/L because of varying infrastructure.<sup>[342]</sup> Patients using well water should have its mineral content checked. Patients with a municipal water supply may have their water checked or confirm analysis of mineral content through their municipality. A water copper content  $>100$   $\mu$ g/L is considered elevated for WD: water treatment to decrease the copper concentration is indicated. Copper levels are highest when taps are first turned on because the water has been sitting in contact with plumbing. Copper plumbing oxidizes and then releases little to no copper into free-flowing water; therefore, it need not be removed from patients' homes. Individuals with WD should be encouraged to use tap water for cooking or drinking after allowing it to run for at least half a minute or until cool. Water filtration systems can lower copper content of home drinking water. Home water filtration systems may be equipped with carbon-based filters or utilize reverse osmosis for metal removal. Carbon-based home water filters (such as a Brita or PUR) can also decrease copper content of tap water, although it is important that these filters be changed at the recommended intervals to ensure proper metal adsorption by the filter.

### Cookware

Unlined copper or bronze cookware can leach copper content into foods, especially when more acidic foods, such as tomatoes, are added. Unlined copper mixing bowls and drinking mugs should be avoided by patients with WD. Otherwise, most copper pots and pans commercially sold are lined with metals such as tin or stainless steel and are safe to use.

## Nutritional support

Individuals with a compromised swallowing ability due to neurologic WD may require measures to reduce aspiration, such as use of thickeners for liquids, and proper supervision by a speech specialist. If swallowing is severely impaired, enteral feeding can maintain

nutritional status while lowering risk of aspiration associated with oral feeding. Most commercially available tube-feeding preparations have added copper, providing approximately 3 mg of copper per day. Various recipes exist for making homemade low-copper tube feeds, but it is advisable for an RD to work closely with individuals for their preparation. Another option is using concentrated commercially available formulas to meet 50% of caloric needs, with the remaining caloric needs met using evaporated whole milk and a carbohydrate modular product (Appendix S3). Commercially prepared pediatric formulas may be an option for adults needing lower copper formulations because their mineral content is lower to meet the RDAs of younger children; in larger volumes they can still provide nutritionally adequate options for adults (Appendix S3). A standard multivitamin without copper is recommended to ensure adequate micronutrient intake.

Patients with WD and advanced liver disease, irrespective of neurological disabilities, may require supplemental nutrition. Given the underlying metabolic disorder, a formal assessment of nutritional status is worthwhile. Dietary supplementation must balance the need to restrict copper content while providing adequate nutrition.

### Guidance statements 19–20

19. Patients with WD should avoid intake of foods and water containing high concentrations of copper, especially during the first year of treatment. Supervision by a registered dietitian (RD) may help to avoid overly restrictive meal patterns or undue anxiety about diet.
20. Patients with WD unable to maintain adequate nutritional intake require dietary management that includes supplements formulated to meet dietary needs while avoiding excess copper intake. Arranging for participation by a knowledgeable RD may be helpful.

## MONITORING OF TREATMENT

The goal of treatment monitoring is to confirm treatment efficacy by demonstrating clinical and biochemical improvement or stability, to ensure adherence to medication and diet, and to identify adverse side effects in a timely fashion. The minimum recommended frequency of monitoring is twice a year. More frequent



**TABLE 10** General laboratory parameter targets for WD treatment modalities, including findings with excessive or inadequate treatment

	Treatment initiation <sup>a</sup>	Maintenance treatment				Overtreatment			Treatment failure on chronic therapy (nonadherence; drug failure)		
	Urinary copper	24-h urinary Cu excretion, µg/24 h	NCC, µg/dl	AST, ALT	TBili, INR	24-h urinary Cu excretion, µg/24 h	NCC, µg/dl	Other	24-h urinary Cu excretion, µg/24 h	NCC, µg/dl	AST, ALT
D-Penicillamine	Increases	~200–500 (≈3–8 µmol/24 h)	5–15	Trend to normal <sup>b</sup>	↓	< 100	< 5	↓↓CPN, ↓↓Cu; sideroblastic anemia; ↓WBC; ↑Fe indices	> 500 (previously in range) <sup>c</sup>	> 15	↑
Trientine	Increases	~150–500 (≈2.4–8 µmol/24 h)	5–15	Trend to normal <sup>b</sup>	↓	< 100	< 5	↓↓CPN, ↓↓Cu; sideroblastic anemia; ↓WBC; ↑Fe indices;	> 500 (previously in range) <sup>c</sup>	> 15	↑
Zinc	No change, then ↓	< 100 (< 1.6 µmol/24 h)	5–15	Trend to normal <sup>b</sup>	↓	< 20	< 5	↓↓CPN, ↓↓Cu; sideroblastic anemia; ↓WBC; ↑Fe indices;	> 100 (previously normal/near-normal)	> 15	↑

Abbreviations: ALT, alanine aminotransferase; AST, aspartate aminotransferase; CPN, ceruloplasmin; Cu, copper; Fe, iron; INR, international normalized ratio; NCC, non-ceruloplasmin-bound copper; TBili, total bilirubin; WBC, white blood cell count; WD, Wilson disease.

<sup>a</sup>Failure to achieve these patterns on initiation of treatment constitutes one kind of treatment failure. Subsequent failure to achieve profiles described under “Maintenance treatment” suggests treatment failure.

<sup>b</sup>Recurrent elevation of serum aminotransferases after a period of normalization suggests loss of drug efficacy or intercurrent hepatic injury, not necessarily nonadherence.

<sup>c</sup>Initially, 24-h urinary copper excretion may drop below the achieved target range because of drug failure or nonadherence and then increase gradually over time with continued ineffective treatment. Reinstitution of oral chelator will yield a sizeable increase in urinary copper excretion, whereas starting zinc will lead to decreased urinary excretion of copper.

monitoring is required during the initial phase of treatment, for those experiencing worsening of symptoms or side effects of medications, and in individuals suspected of nonadherence to therapy. Physical examination should look for evidence of liver disease and neurological symptoms. For patients on D-penicillamine, cutaneous changes should be sought on physical examination. A careful history should also include questioning about psychiatric symptoms, especially depression. Repeat examination for KF rings should be performed if there is a question of the patient's adherence because their appearance in a patient in whom they were previously absent or reappearance may portend onset of symptomatic disease.

Laboratory testing at baseline and over time should include liver biochemistries, tests of hepatic synthetic function, total blood count, and indices of copper metabolism (serum copper, ceruloplasmin, 24-h urinary copper excretion) and routine urinalysis (for those on chelation therapy). Estimated NCC may provide the best guide to treatment efficacy; however, it may be incalculable if either parameter is below the laboratory detection limit. Analysis of 24-h urinary copper excretion on medication (or after treatment washout, which reflects overall total-body copper burden) is helpful for monitoring adherence and making dosage adjustments. Urinary copper testing should be performed at least annually, although twice yearly may be better for patients with a history of nonadherence or after dose adjustments. When improved assays for NCC are available, this may be a surrogate for disease control and used for monitoring adherence, as well as for making therapeutic changes. Biochemical treatment targets may be helpful (Table 10).

Evidence of nonadherence to diet or therapy includes clinical worsening, elevation of liver tests, and an increased urinary copper excretion; hepatic deterioration may follow.<sup>[74]</sup> Disproportionately low urinary copper excretion on chelation treatment relative to steady state values for that individual on treatment can indicate overtreatment, and this is often accompanied by a lower serum ceruloplasmin and serum copper and therefore lower NCC. Neutropenia and anemia, as well as hyperferritinemia, can also be present with overtreatment. Patients who have stopped their oral chelation therapy relatively recently or are taking subtherapeutic dosages may also have low values for 24-h urinary copper excretion, but these individuals typically have elevated NCC or CuEXC or increased serum copper. Adherence in patients taking zinc can also be checked by measuring serum zinc or 24-h urinary zinc excretion.

## Treatment failure

Treatment failure may occur with any WD medication, either at initiation of treatment or during maintenance

therapy. These situations appear similar but may be subtly different. Failure of therapy should prompt consideration of its etiology. Once concurrent disease and nonadherence are excluded, pharmacological therapy should be re-evaluated and likely altered. For patients who have more advanced liver disease or develop liver failure, evaluation for liver transplantation should be considered. Currently, no surrogate markers are established for evaluating treatment failure.

Failure of therapy at treatment initiation represents failure to stabilize disease either clinically or biochemically (or both) and, unique to the liver, progression of hepatic fibrosis. Clinical failure includes progressive hepatic, neurological, or psychiatric disease. With hepatic disease, failure includes onset of decompensation (new onset of ascites, encephalopathy, or variceal bleeding) or inability to stabilize a patient with decompensated cirrhosis (refractory ascites, severe encephalopathy, or worsening jaundice and coagulopathy). For neurological disease, failure involves the progression of symptoms despite therapy, in particular, the paradoxical acceleration of neurological disease or development of new symptoms. There may be worsening psychiatric disease, including onset of psychosis, worsening depression, or mania.

Biochemical failure at initiation of treatment involves the inability to prevent worsening or exacerbation of liver injury. This may be assessed using parameters of liver injury such as serum aminotransferases. Inability to reduce these to less than twice (i.e., <2 times) the upper limit of normal over time indicates treatment failure; however, the time interval for achieving improvement may depend on the magnitude of the initial elevation. Synthetic function of the liver may take longer to respond to therapy than aminotransferases, typically 3–18 months. INR is a good measure of synthetic function, as is albumin, apart from its confounders such as nutrition and acute-phase variability. Bilirubin clearance is affected by liver function: serum bilirubin should decrease at approximately the same rate as synthetic function improves. It may be confounded by hemolysis or concurrent Gilbert syndrome and thus should not be used in isolation. For patients with cirrhosis, the MELD score may be calculated and followed, with the expectation that it should improve over 3–18 months' time. In patients with MELD scores >15 who are worsening or failing to improve after 3 months, evaluation for liver transplant may be necessary (see indications for liver transplant).

Measuring 24-h urinary copper excretion on treatment can be highly informative, although results must be judged in relation to drug, drug dose, and stage of treatment (initial or maintenance). It should be measured at least annually. With continued adequate treatment, 24-h urinary copper excretion decreases over time from initial high values to lower amounts.<sup>[297,343]</sup> For those on oral chelators, some prefer to measure 24-h urinary copper excretion after a 48-h washout period off drug.<sup>[297]</sup> Notably, in patients treated with zinc

chronically, rising 24-h urinary copper excretion (typically  $>100 \mu\text{g}/24 \text{ h}$ ) after some period of achieving normality suggests treatment failure.

Progression of hepatic fibrosis despite therapy also constitutes treatment failure, due to failure of pharmacotherapy or independent liver injury from an unrelated process. Monitoring can be by elastography or with use of serum-based assays such as Fibrosis-4 (Fib-4) Index or AST/platelet ratio. The gold standard remains liver biopsy. Here, the biopsy can be valuable for grading and staging injury and diagnosing concurrent disease.

For patients on maintenance therapy who, by definition, had achieved clinical stability, worsening of disease or onset of new symptoms (e.g., neurological symptoms in someone with only hepatic disease) or progressive hepatic fibrosis constitutes treatment failure. In any such patient with possible treatment failure, it is important to exclude concurrent disease and to distinguish it from undertreatment (inadequate dosage of therapy) or ineffective pharmacotherapy. Undertreatment may be due to nonadherence to treatment or diet, and in this case, a change in pharmacotherapy may not be warranted. Instead, dose alteration or stricter supervision and close monitoring may be sufficient to restore stability. For those with pharmacological failure, a change in treatment is appropriate and can be immediately accomplished, without any weaning strategy. It is uncertain whether addition of a second therapy to an ongoing treatment is better than just changing treatment or dose adjustment alone: this needs to be individualized because there are insufficient data for guidance.

### Guidance statements 21–24

21. For regular monitoring, liver biochemistries and INR, complete blood count and routine urinalysis (especially for those on chelation therapy with D-penicillamine or trientine), and physical examination should be performed regularly, at least twice per year. Patients receiving chelation therapy require a complete blood count and urinalysis regularly, no matter how long they have been on treatment.
22. The 24-h urinary copper excretion while on medication, or in patients on D-penicillamine or trientine after a temporary period (48 h) off drug, should be measured yearly and more frequently if there are questions regarding adherence or if the medication dosage is adjusted. Serum copper and ceruloplasmin may be followed for trends: very high or very low serum copper or serum copper disproportionately high for simultaneous serum

ceruloplasmin. These may disclose exogenous copper intake (higher copper) or total-body depletion (lower copper and ceruloplasmin).

23. Overtreatment of WD by pharmacological therapy directed at removing or detoxifying copper may be indicated by development of cytopenias or retention of tissue iron associated with raised serum ferritin. It is confirmed by a low serum copper and a very low 24-h urinary copper output. For oral chelators, 24-h urinary copper excretion disproportionately low for the dose of chelator being administered (below therapeutic target, specifically  $<100 \mu\text{g}/24 \text{ h}$  or  $<1.6 \mu\text{mol}/24 \text{ h}$ ) suggests overtreatment. For zinc therapy, 24-h urinary copper  $<20 \mu\text{g}/24 \text{ h}$  ( $<0.3 \mu\text{mol}/24 \text{ h}$ ) suggests overtreatment. Once overtreatment is confirmed, dose reduction or brief interruption of medical therapy should be instituted, with close follow-up for reassessment.
24. Treatment failure may occur during treatment initiation or while on chronic treatment. It can complicate any WD medication. Concurrent diseases and nonadherence must be excluded. Pharmacological therapy should be revised in patients with treatment failure; however, with more advanced liver disease or liver failure, liver transplantation may be required.

## ADHERENCE

Once WD is conclusively diagnosed and treatment has been initiated, pharmacological treatment is lifelong. The only exception to maintaining lifelong treatment for WD is after liver transplantation, when chelators or zinc can be stopped, although treatments for maintenance of the liver graft are required. Survival of patients with WD who receive effective pharmacological treatment approaches the normal longevity of their country.<sup>[32,344–348]</sup> With hepatic WD, effective treatment instituted early makes it unlikely that neurological abnormalities will develop.<sup>[349]</sup> Effective treatment is efficacious, well tolerated, and actually taken consistently by the patient.

The inherent challenges to maintaining lifelong treatment are increasingly being appreciated. As with most chronic diseases, such as diabetes mellitus and cystic fibrosis, adolescence is a difficult phase when the need for daily treatment may be questioned and rejected. Treatment for an asymptomatic disorder, such as essential hypertension, is known to be fraught with problems of adherence.<sup>[350]</sup>

Treatment of WD faces similar issues. When treatment is initiated in asymptomatic persons, adherence to the medical regimen is necessary to avoid the development of symptomatic WD. Asymptomatic patients with WD are prone to nonadherence, potentially leading to fatal hepatic failure.<sup>[351]</sup> A short-term study found that taking medication for WD absolutely consistently was a standard often not achieved.<sup>[352]</sup> Furthermore, subtle neuropsychiatric changes affecting executive function, consequent to the nonadherence, might impede adherence further. The root causes of nonadherence in WD are diverse. They include incomplete buy-in for the diagnosis itself among asymptomatic patients, a false sense of security after prolonged treatment for WD, inconvenience of the medical regimen, and issues relating to drug supply and cost.

Identifying contributors to nonadherence in WD can help formulate coping strategies. Patient education about WD and its treatment is critically important. A goal of managing a smooth transition from pediatric to adult clinics is enhanced adherence. Although it has not been studied in WD, the experience with pediatric liver transplant recipients transitioning to adult clinics may be highly instructive.<sup>[353]</sup> Regular medical follow-up is equally important and must include a specific focus on adherence to the drug treatment. If seeing a specialist for their WD care and follow-up poses economic or logistic hardship for the patient, arrangements can be established so that a local healthcare provider provides regular follow-up and communicates with the specialist center where the patient may be seen in person less frequently. Erratic attendance for follow-up appointments may signal nonadherence. Irregularity in getting prescription refills may point to nonadherence or to problems with affording medication. Partnership of the prescribing physician with a specialty or dedicated pharmacy that monitors medication refills can help identify those not renewing or erratically obtaining their medications early on. In patients, once serum aminotransferases have normalized with treatment, an unexplained rise in serum aminotransferases may indicate a problem with adherence. Measuring 24-h urinary excretion of zinc along with copper (in the same collection) can provide a biochemical method for monitoring adherence in patients treated with zinc. Reappearance of KF rings after their previous resolution and disappearance typically signals nonadherence.

The potential difficulty of taking medication 2–3 times daily away from meals needs to be acknowledged, along with suggestions for how to manage it. Such aids can include a convenient weekly pillbox with each day's pills placed in a separate compartment, a smartphone scheduling device, and regular phone check-ups by a medical team member. Switching to the heat-stable form of trientine may be important for some patients. Taking zinc with a small amount of protein (e.g., slice of lunch meat) or changing to a different zinc salt may obviate gastric distress. A

French study suggests that a comprehensive team approach may increase the patient's sense of being supported and thus reduce risk of nonadherence.<sup>[352]</sup> Novel methods of general support and oversight for patients, for example, via smartphone or social networks, have not been evaluated in WD. Sensitivity to the patient's changing social needs from young adulthood through older age is required. Physicians' awareness of the patient's changing economic resources, for example, upon loss of insurance coverage due to job loss or retirement, is important. A positive and nonjudgmental attitude from the medical team is essential.

Stopping treatment altogether may precipitate a clinical catastrophe.<sup>[73,264,354]</sup> Recurrence of presenting features of neurologic WD or development of new neurological features may occur within a few months of stopping treatment. Although biochemical changes in serum aminotransferases occur typically within 3–6 months, development of clinical signs of progressive liver injury may take much longer. Resuming treatment may not rescue patients who develop liver failure: in these individuals, liver transplantation is required.

#### Guidance statement 25

25. Ensuring adherence to a well-defined treatment plan for WD is critically important for patients to achieve good outcomes with therapy. Regular clinical assessments and a broadly supportive approach, team-based if possible, are elements of achieving good adherence. Monitoring frequency should be increased in patients where nonadherence is suspected.

## TREATMENT IN SPECIFIC CLINICAL SITUATIONS

### Decompensated cirrhosis

Patients with WD presenting initially with chronic liver disease and decompensated cirrhosis, typically with hypoalbuminemia, coagulopathy, jaundice, and ascites, but variable encephalopathy were traditionally treated with chelation therapy for their WD. Recently, “combination” therapy with either D-penicillamine<sup>[164,291]</sup> or trientine<sup>[355]</sup> and zinc has been utilized as an intensive regimen for severe disease. The two medications must be temporally dispersed throughout the day in at least



four doses, with usually 4–5 h between administration of either drug, in order to avoid having chelator bind the zinc and thus compromise efficacy. For example, elemental zinc (50 mg in adults, 25 mg in children) is taken as the first and third doses and trientine (approximately 10 mg/kg) as the second and fourth doses. Any patient starting this regimen should be simultaneously evaluated for liver transplantation. Patients who are slow to respond or failing this regimen should be promptly considered for liver transplant. Prognostic scoring systems such as the NWI, especially when applied serially, may help identify patients who will respond or fail treatment. Those who respond may be transitioned to full-dose zinc or full-dose trientine (or D-penicillamine) as monotherapy after approximately 3–6 months when disease stabilization is achieved. This treatment strategy remains investigational despite some supportive data.<sup>[164,291,355]</sup>

### Guidance statements 26–27

26. Patients with WD and severe hepatic disease (irrespective of severity of their neurological disease) may respond to an intensive medical regimen. They require liver transplantation evaluation as backup. Longitudinal assessment with a prognostic scoring system may help identify those where medical therapy is likely to succeed.
27. Patients with WD and advanced chronic liver disease who fail to respond to or tolerate medical therapy should be considered promptly for liver transplantation.

## Treatment of acute liver injury (ALI)

ALI discussed here describes acute severe liver injury due to WD with severe coagulopathy unresponsive to vitamin K administration but without associated hepatic encephalopathy. Although these patients may fulfill the traditional liver transplantation criteria, they may respond to an intensive medical regimen as for decompensated cirrhosis (chelation combined with zinc). Use of oral chelation therapy has led to survival and improvement of liver function of select patients, especially (but not limited to) those who have an NWI score of <11.<sup>[120,164]</sup> Liver transplantation should be considered in those presenting with severe ALI, more so if the NWI score is >10 and fails to decrease over time.

Longitudinal application of evaluative scores may help identify response to medical treatment or emerging

need for transplantation. Some patients presenting with ALI progress to ALF, and these patients require liver transplantation.

## Treatment of ALF due to WD

Patients with ALF due to WD require liver transplantation, which is lifesaving because recovery with medical therapy alone is rare. Optimal medical management requires that liver transplantation be available to the center where the patient is treated. Treatment with oral chelators may contribute to stabilization so long as renal function is intact or renal support is being provided; however, acute hypersensitivity reactions and marrow suppression are a concern for their use if transplant is imminent. Where chelation cannot be used, zinc may be administered, despite its slow onset of action.

Aggressive medical management according to established protocols for ALF (including treatment of hyperammonemia and detection and management of cerebral edema), with early consideration of apheresis or renal replacement therapy to rapidly remove circulating copper, may stabilize the patient with WD awaiting transplantation. Plasmapheresis, plasma exchange, albumin dialysis, exchange transfusion, renal replacement therapy, molecular absorbance recirculating system (MARS), or combinations of these treatments can reduce hemolysis and help prevent renal tubular injury from copper and copper complexes. Such interventions may stabilize patients with ALF due to WD and delay, but typically not eliminate, the need for transplantation.<sup>[356–369]</sup> In rare cases (<10% overall), the patient may respond well enough that liver transplant is not required.<sup>[236,370]</sup> This very low rate of survival without liver transplantation highlights the importance of an expedited transplant evaluation.

Patients with ALF due to WD are appropriately afforded the highest category of priority for liver transplantation by the United Network for Organ Sharing, status 1A, and by Eurotransplant despite the recognition of the underlying chronic liver injury with advanced fibrosis in these patients.<sup>[72]</sup>

## Liver transplantation for WD

### Indications

Liver transplantation is indicated for patients with WD and decompensated liver disease unresponsive to medical therapy, or ALI progressing to ALF, or ALF with the classic presentation (intravascular hemolysis, relatively low serum aminotransferases, very low serum alkaline phosphatase, progressive hepatic encephalopathy). Certain other types of patients with WD may require liver transplantation.



**TABLE 11** Outcomes of liver transplantation for Wilson disease

First author, year of publication	Place	Time period	n	Population		Indication			Follow-up, years	Patient survival, %			Graft survival, %		
				Adult	Child	CLD	ALF	Neuro		1 year	5 year	10 year	1 year	5 year	10 year
Schilsky et al., 1994 <sup>[237]</sup>	USA	—	55 (62 LT)	—	—	33	21	1	2.5	79	—	—	—	—	—
Eghtesad et al., 1999 <sup>[375]</sup>	USA	1971–1993	45 (56 LT)	26	16	15	30	0	5	—	73	69	—	58	54
Emre et al., 2001 <sup>[72]</sup>	USA	1988–2000	17 (21 LT)	14	3	6	11	0	5.3	88	—	—	62	—	—
Sutcliffe et al., 2003 <sup>[438]</sup>	UK	1988–2000	24 (25 LT)	—	—	—	—	—	8	—	87	—	—	87	—
Wang et al., 2005 <sup>[388]</sup>		2001–2003	22	3	19	20	2	9	1.5	95	—	—	95	—	—
Medici et al., 2005 <sup>[378]</sup>	Italy	1985–2000	37 (41 LT)	—	—	8	29	0	—	—	75	60	—	70	47
Sevmis et al., 2008 <sup>[439]</sup>		2001–2007	24 (24 LT)	—	—	16	18	0	1.8	—	79	—	—	76	—
Cheng et al., 2009 <sup>[440]</sup>	China	2001–2007	36 (36 LRLT)	—	—	32	2	2	3.7	—	75	—	—	75	—
Yoshitoshi et al., 2009 <sup>[441]</sup>	Japan	1992–2006	32 (32 LRLT)	8	24	11	21	0	6.7	—	84	80	—	88 <sup>a</sup>	83 <sup>a</sup>
Armon et al. (UNOS), 2011 <sup>[371]</sup>	USA	1987–2008	570 (n/a)	400	170	—	—	—	—	—	89, ch 86, ad	—	—	—	—
Armon et al. (UNOS), 2011 <sup>[371]</sup>	USA	2002–2008	170 (n/a)	119	51	67	103	0	—	—	100/88 <sup>b</sup> , ch 90/90 <sup>b</sup> , ad	—	—	100/ 82 <sup>b</sup> , ch 86/86 <sup>b</sup> , ad	—
Guillaud et al., 2014 <sup>[390]</sup>	France	1985–2009	121 (140 LT)	75	46	55	59	7	6	—	87	87	—	80	79
Ferrarese et al., 2020 <sup>[442]</sup>	Italy	2006–2016	27 (27 LT)	27	0	24	1	2	—	—	88	83	—	88	82

Abbreviations: ad, adults; ALF, acute liver failure; ch, children; CLD, chronic liver disease; LT, liver transplant (deceased donor); LRLT, living-related liver transplant; n/a, type not reported; neuro, neurologic Wilson disease; UNOS, United Network for Organ Sharing.

<sup>a</sup> Data are for ABO compatible grafts; graft survival was 67% at 5 years and 67% at 10 years for ABO (blood type) incompatible grafts.

<sup>b</sup>Results are provided as CLD/ALF regarding indication.

Patients with WD and progressive chronic liver failure must also be considered for liver transplantation. They are often older by 10–20 years than those with ALF due to WD<sup>[371]</sup> and are frequently identified only later in the course of their disease. Some of these patients represent a late diagnosis of WD, and although medical therapy has been tried, the patient has not responded well to treatment. Others are patients in whom therapy has become ineffective, usually due to nonadherence but rarely due to intrinsic failure of drug action. These patients often present with jaundice, ascites, hepatic encephalopathy, varices, and other complications of portal hypertension. In addition, unresectable HCC is also an indication for liver transplant if the tumor is confined to the liver without vascular invasion according to Milan criteria.<sup>[372]</sup>

Liver transplantation has not been recommended as primary treatment for neurologic WD because the liver disease is stabilized by medical therapy in most of these individuals, and outcomes with liver transplantation are not always beneficial.<sup>[72,373–377]</sup> Patients with neurological or psychiatric disease due to WD had poorer outcomes and difficulties with adherence to medical regimens after liver transplantation.<sup>[378]</sup> However, some who underwent transplantation for decompensated cirrhosis had psychiatric or neurological symptoms that improved following liver transplantation.<sup>[237,375,379]</sup> Weiss et al. reported improvement of neurological symptoms in long-term survivors of liver transplantation.<sup>[380]</sup> There are scattered case reports and series of individuals transplanted for neurologic WD that improved after liver transplantation,<sup>[381–384]</sup> but detailed data on the neurological evaluations of these patients are not available. A study featuring extensive characterization of severe neurological disorder in WD, mainly dystonia or parkinsonism, showed that liver transplantation could improve neurological status in selected patients and achieve good survival; however, this was a comparatively small, uncontrolled study,<sup>[385]</sup> insufficient to sway current recommendations. Further controlled clinical trials are required to validate neurologic WD as a primary indication for liver transplantation.

## Donor organs and type of transplant

Although the majority of patients undergoing liver transplant for WD in North America and Europe have received deceased donor organs, living-donor liver transplants can also be performed. Successful living-donor liver transplant is possible when the donor is a family member who is a heterozygote carrier for WD.<sup>[386–390]</sup>

## Outcome

Liver transplantation corrects the hepatic metabolic defects of WD and permits normalization of extrahepatic

copper disposition without WD treatment. Long-term patient and graft survival for both adults and children continues to be excellent (summarized in Table 11).

### Guidance statements 28–31

28. Patients with ALF due to WD should be referred for a liver transplant evaluation and potential liver transplantation immediately.
29. Patients with ALI due to WD may respond to medical therapy or may progress to ALF. They require early transplant referral and evaluation.
30. After liver transplantation, medical treatment specific for WD is unnecessary.
31. Liver failure and HCC are well-accepted indications for liver transplantation in WD; however, neurologic WD remains a controversial indication.

## Liver cancer in WD

HCC has been regarded as a rare complication of WD. Annual risk of HCC in patients with WD and cirrhosis was estimated as 0.14%.<sup>[391]</sup> By contrast, HCC was reported in 7% of patients with WD in a Saudi Arabian cohort.<sup>[392]</sup> HCC in WD therefore may be more frequent than formerly appreciated but still less frequent than in other chronic liver diseases.<sup>[393–397]</sup> There also is a substantial rate of intrahepatic CCA complicating WD.<sup>[398]</sup> Therefore, in WD, unless an apparent liver tumor meets strict radiologic criteria for HCC and cirrhosis is present, the tumor should be evaluated according to current guidelines.<sup>[372]</sup> Hepatic cancer complicating WD may occur in the pediatric age-bracket.<sup>[399,400]</sup>

Treatment of liver cancer in WD should follow standard guidelines for treatment of HCC and CCA.<sup>[372]</sup> When possible, resection should be first-line therapy for HCC and CCA, and liver transplant should be considered in appropriate patients. Other oncologic treatments for liver cancers are evolving and may be appropriate for treatment of nonresectable and non-transplantable liver cancer in patients with WD.

Screening and surveillance for HCC is recommended for patients with WD and cirrhosis or regressed cirrhosis and not for noncirrhotic patients.

### Guidance statement 32

32. Patients with WD with cirrhosis or regressed cirrhosis should undergo screening and

surveillance for HCC according to the recommended guidelines. Screening and surveillance for CCA is not indicated in WD; however, CCA should be considered in the differential diagnosis of liver tumors not meeting strict radiologic criteria for HCC.

## Pregnancy

Whenever possible, advance planning is beneficial. Ideally, the patient is in good general health and with clinically stable WD prior to conception. Fertility appears to be normal in patients diagnosed early with hepatic WD who are clinically stable on effective treatment.<sup>[401]</sup> Switching WD treatment from an oral chelator to zinc ahead of pregnancy is an option; however, any such change must be shown to maintain the patient's good clinical condition prior to the pregnancy. Folate supplementation may be started prior to conception to reduce fetal risk of open neural tube defects. Although not mandatory, determining the partner's *ATP7B* genotype may identify an unsuspected heterozygote, a finding with important implications for the infant's risk of inheriting WD. Women with WD may have increased difficulty conceiving,<sup>[402,403]</sup> although stability on treatment appears to mitigate this problem.<sup>[403]</sup> Although rare, untreated WD is a recognized cause of recurrent spontaneous abortion. Patients with WD and current/previous decompensated cirrhosis should be counseled to avoid pregnancy because it can pose risks to both mother and fetus.<sup>[404]</sup>

An interdisciplinary approach coordinating input from relevant subspecialties can help optimize management of the pregnancy.<sup>[405]</sup> Appropriate referrals should be arranged early on. Treatment must be maintained throughout the course of pregnancy for all patients with WD. Interruption of treatment during pregnancy has resulted in ALF<sup>[406]</sup> or in some degree of (usually reversible) clinical deterioration.<sup>[407]</sup> The dosage of zinc is maintained throughout without change; in contrast, dosages of chelating agents should be reduced to the minimum necessary to maintain clinical and biochemical stability during pregnancy. Such a dose reduction is approximately 25%–50% of the pre-pregnancy dose. It should be made, if possible, in the first trimester to benefit the developing fetus. It can still be made any time thereafter during the pregnancy, preferably by the beginning of the third trimester. Dose reduction of chelation may be especially important for the mother if cesarean section is anticipated, in order to promote good wound-healing. This lower dose can be continued for 2–3 weeks after delivery, and then the pre-pregnancy dose can be resumed. During pregnancy,

patients should be monitored frequently for their WD, approximately once per trimester. Those with portal hypertension may require delivery in a specially equipped high-risk obstetrics unit. Endoscopic visualization of gastroesophageal varices should prompt treatment with a nonselective beta-blocker or variceal banding. This is important because vascular volumes increase during the course of the pregnancy, thereby potentially increasing portal pressure.

Experience to date indicates the chelating agents (both D-penicillamine and trientine) and zinc salts have been associated with satisfactory outcomes for the mother and fetus.<sup>[403,408,409]</sup> Treatment with oral chelators in the first trimester is not necessarily untoward for the fetus.<sup>[410]</sup> The occurrence of a few birth defects has been noted infrequently in the offspring of treated patients, notably with D-penicillamine thyroid abnormalities<sup>[411]</sup> and diffuse cutis laxa.<sup>[412]</sup> D-Penicillamine is listed specifically as an FDA category D teratogen, and trientine is listed as an FDA category C teratogen. In general, the rarity of WD has made it difficult to determine whether the frequency of these defects is different from that in the population at large; however, it seems to be similar.<sup>[403]</sup>

Because *ATP7B* in mammary tissue evidently plays a role in the delivery of copper into breast milk,<sup>[413]</sup> concentrations of breast milk copper in mothers with WD may be inadequate for the newborn's metabolic and developmental needs. D-Penicillamine is excreted into breast milk and has potential to harm the infant. Women need to be aware of the possible risk; appropriate arrangements for evaluating the baby (regular checks of complete blood count) are advisable. Few data are available about the excretion of trientine into breast milk. Bioavailability of zinc in breast milk is ordinarily quite high,<sup>[414]</sup> and little is known about the effect of pharmacological doses of zinc on breast milk concentrations.<sup>[415–417]</sup>

WD may first become clinically apparent during pregnancy: timely diagnosis is complicated but essential. The differential diagnosis includes conditions that are more commonly found during pregnancy: hemolysis–elevated liver enzymes–low platelets syndrome, acute fatty liver of pregnancy, thrombotic thrombocytopenia purpura, antiphospholipid syndrome, and flare of systemic lupus erythematosus.<sup>[405]</sup> These may resemble WD in some respects. Adverse pregnancy outcomes are associated with undiagnosed WD.<sup>[403]</sup>

### Guidance statements 33–35

33. Preconception counseling should include genetic counseling and discussion of medication safety in pregnancy and should consider the prospective mother's health.

34. Treatment for WD should be continued during pregnancy. D-Penicillamine has known teratogenic potential; data for trientine are sparse. Clinical experience suggests that chelation therapy at a reduced dosage with monitoring of liver function each trimester is another option. Zinc is safe; however, if a prospective mother is switched to zinc prior to pregnancy, clinical stability on zinc should be established before the pregnancy occurs.
35. Breastfeeding, despite its recognized benefits, entails potential harms to the infant while a lactating mother is on treatment for WD. The pros and cons should be weighed in each case.

## SYMPTOMATIC TREATMENT (NONHEPATIC)

### Treatment of neurological symptoms

Effective management of neurological manifestations of WD requires the restoration of normal copper balance, achieved typically through pharmacotherapy. It is important to monitor neurological symptoms closely when initiating D-penicillamine or trientine treatment because these can cause paradoxical neurological decline, especially if dosing is too aggressive (initial dose too high or dose increase too rapid).<sup>[73,280,418,419]</sup> In most cases, this paradoxical worsening is thought to be due to a transient increase in NCC (or exchangeable plasma copper),<sup>[420]</sup> which is in equilibrium with CNS copper.

Many neurological symptoms are at least partially responsive to adjunctive medical management (see Table 2). Medications to treat parkinsonism, such as carbidopa/levodopa, are not necessarily effective.<sup>[34]</sup> Treatments for dystonia can be extremely helpful but may be limited by adverse effects (trihexyphenidyl: anticholinergic effects; clonazepam: sedation; baclofen: abnormal liver tests). Focal dystonia can often be effectively treated with botulinum toxin injection, which may need to be repeated over time.<sup>[421]</sup> Deep brain stimulation targeting the ventral intermediate nucleus of the thalamus for tremor and the globus pallidus interna for dystonia has been tried, but with only variable success in a limited number of patients.<sup>[422]</sup> Chorea may respond to vesicular monoamine transporter-2 inhibitors, such as tetrabenazine, or dopamine receptor antagonists, although patients with WD may develop adverse effects from neuroleptics.<sup>[423]</sup> Taking a multidisciplinary approach involving speech therapy for

dysarthria and dysphagia, as well as physical therapy and occupational therapy, is often helpful. Swallowing studies may identify those with dysphagia and risk of aspiration risk requiring intervention.

### Treatment of psychiatric symptoms in WD

Treatment of WD directed at removal of pathological copper deposition leads to an improvement in psychiatric symptoms in most cases.<sup>[424,425]</sup> Approximately one third of patients with psychiatric symptoms will improve with decoppering treatment alone.<sup>[426]</sup> If psychiatric symptoms do not resolve with primary treatment of WD alone or if they are severe, psychotropic medication or psychotherapy can be utilized along with pharmacotherapy for WD. Reported trials of treatments include use of psychotropic medications, such as lithium, haloperidol, tricyclic antidepressants, benzodiazepines, quetiapine, risperidone, and clozapine, as well as use of electroconvulsive therapy (ECT).<sup>[43,52,427,428]</sup>

Typical or atypical antipsychotics were used to good clinical effect; however, careful oversight is needed because patients with WD are very sensitive to neuroleptics and are prone to develop extrapyramidal symptoms.<sup>[43,423,429]</sup> Lower potency antipsychotics are less likely to cause extrapyramidal symptoms (such as quetiapine), and titrating the dosage slowly may help avoid these adverse effects.<sup>[430]</sup> Clozapine,<sup>[427]</sup> quetiapine,<sup>[428]</sup> and olanzapine<sup>[431]</sup> were used effectively to treat psychiatric symptoms in patients with WD. Because some patients with WD are more vulnerable to agranulocytosis due to hypersplenism and/or D-penicillamine-associated bone marrow suppression, clozapine might not be a suitable option.<sup>[427]</sup>

For bipolar disorders, lithium is the preferred agent, considering its renal excretion and lack of hepatic metabolism. Lithium also stimulates granulocyte production and is potentially safer than clozapine in certain patients.<sup>[431]</sup> Lithium may exaggerate tremor already present in some patients with WD.

ECT for control of acute psychosis of WD was reported for patients who had extrapyramidal symptoms along with psychosis.<sup>[432]</sup> ECT should only be considered for select patients with WD.

### Guidance statements 36–38

36. Effective treatment restoring normal copper balance may lead to improved neurological and psychiatric features of WD.
37. Adjunctive medical treatment may alleviate symptoms of neurologic WD, including parkinsonism, dystonia, and chorea.



38. Patients with WD with persisting or severe psychiatric features, despite adequate WD treatment, may benefit from psychotropic medications or counseling.

## CONCLUSION

WD is an uncommon but eminently treatable genetic disorder due to abnormalities of hepatocellular copper disposition, associated with dysfunction of the P-type ATPase ATP7B. It may present at any age. Clinical presentation is typically hepatic, neurological, or psychiatric; more than one manifestation may be present. Asymptomatic patients are most often identified via screening of a proband's first-degree relatives. Genetic evaluation of *ATP7B* can expedite diagnosis and is efficient for screening. Medical therapy remains highly effective, even for those with cirrhosis, so long as adherence to lifelong treatment is attained. Liver transplantation is lifesaving for those who fail medical therapy or present with ALF. A multidisciplinary team approach optimizes overall management of patients with WD.

## AUTHOR CONTRIBUTIONS

Michael L. Schilsky and Eve A. Roberts contributed substantially to the conception and design of the paper; acquisition of data; analysis and interpretation of data; drafting the paper and revising it extensively and critically for important intellectual content. Jeff M. Bronstein, Anil Dhawan, James P. Hamilton, Anne Marie Rivard, May Kay Washington, Karl Heinz Weiss, and Paula C. Zimbrea contributed to the conception and design; acquisition, analysis and interpretation of data; drafting the paper and revising it critically for important intellectual content. All authors provided final approval of the versions to be published.

## ACKNOWLEDGEMENTS

The authors are grateful for the valuable contributions of the American Association for the Study of Liver Diseases (AASLD) Practice Guideline Committee (PGC), particularly Anjana A. Pillai and Elizabeth Rand. Members of the PGC include Elizabeth C. Verna (chair), George Ioannou (chair), Rabab Ali, Scott W. Biggins, Roniel Cabrera, Henry Chang, Michael F. Chang, Po-Hung Chen, Kathleen Corey, Archita Parikh Desai, Albert Do, David S. Goldberg, Saul J. Karpen (board liaison), W. Ray Kim (board liaison), Lindsay King, Cynthia Levy, Jeff McIntyre, Jessica L. Mellinger, Anthony J. Michaels, Andrew Moon, Mindie H. Nguyen, Nadia Ovchinsky, Anjana A. Pillai, Daniel S. Pratt, Ashwani K. Singal,

Elizabeth Rand, Hugo R. Rosen, Adrienne Simmons, Matthew J. Stotts, Christopher J. Sonnenday, Puneeta Tandon, and Lisa B. VanWagner.

## FUNDING INFORMATION

Funding for the development of this Practice Guidance was provided by the AASLD.

## CONFLICT OF INTEREST

Michael L. Schilsky received grants from Orphan, Vivet Therapeutics, and Alexion. Jeff M. Bronstein advises and received grants from Alexion and Ultragenix. Anil Dhawan consults for Alexion. He advises Univari and Orphan. Mary Kay Washington consults for Takeda. Karl Heinz Weiss consults for, advises, is on the speakers' bureau for, and received grants from Univari, Alexion, and Orphan. He advises Pfizer, Desitin, Ultragenix, Vivet Therapeutics, and Bayer. He received grants from Novartis. Paula C. Zimbrea consults for and advises Alexion. She consults for Vivet Therapeutics and Ultragenix.

## REFERENCES

1. Wilson SAK. Progressive lenticular degeneration: a familial nervous disease associated with cirrhosis of the liver. *Brain*. 1912;34:295–507.
2. Bearn AG. A genetical analysis of thirty families with Wilson's disease (hepatolenticular degeneration). *Ann Hum Genet*. 1960;24:33–43.
3. Walshe JM. History of Wilson's disease: 1912 to 2000. *Mov Disord*. 2006;21:142–7.
4. Bonn -Tamir B, Farrer LA, Frydman M, Kanaaneh H, Rao DC. Evidence for linkage between Wilson disease and esterase D in three kindreds: detection of linkage for an autosomal recessive disorder by the family study method. *Genet Epidemiol*. 1986;3: 201–9.
5. Bull PC, Thomas GR, Rommens JM, Forbes JR, Cox DW. The Wilson disease gene is a putative copper transporting P-type ATPase similar to the Menkes gene. *Nat Genet*. 1993;5:327–7.
6. Tanzi RE, Petrukhin K, Chernov I, Pellequer JL, Wasco W, Ross B, et al. The Wilson disease gene is a copper transporting ATPase with homology to the Menkes disease gene. *Nat Genet*. 1993;5:344–50.
7. Yamaguchi Y, Heiny ME, Gitlin JD. Isolation and characterization of a human liver cDNA as a candidate gene for Wilson disease. *Biochem Biophys Res Commun*. 1993;197:271–7.
8. Holtzman NA, Gaumnitz BM. Studies on the rate of release and turnover of ceruloplasmin and apoceruloplasmin in rat plasma. *J Biol Chem*. 1970;245:2354–8.
9. Frydman M. Genetic aspects of Wilson's disease. *J Gastroenterol Hepatol*. 1990;5:483–90.
10. Sandahl TD, Laursen TL, Munk DE, Vilstrup H, Weiss KH, Ott P. The prevalence of Wilson's disease: an update. *Hepatology*. 2020;71:722–32.
11. Coffey AJ, Durkie M, Hague S, McLay K, Emmerson J, Lo C, et al. A genetic study of Wilson's disease in the United Kingdom. *Brain*. 2013;136:1476–87.
12. Jang JH, Lee T, Bang S, Kim YE, Cho EH. Carrier frequency of Wilson's disease in the Korean population: a DNA-based approach. *J Hum Genet*. 2017;62:815–.
13. Collet C, Laplanche JL, Page J, Morel H, Woiman F, Poujois A. High genetic carrier frequency of Wilson's disease in France:



- discrepancies with clinical prevalence. *BMC Med Genet*. 2018; 19:143.
14. Wallace DF, Dooley JS. ATP7B variant penetrance explains differences between genetic and clinical prevalence estimates for Wilson disease. *Hum Genet*. 2020;139:1065–75.
  15. Steindl P, Ferenci P, Dienes HP, Grimm F, Pabinger I, Madl C, et al. Wilson's disease in patients presenting with liver disease: a diagnostic challenge. *Gastroenterology*. 1997;113:212–8.
  16. Iorio R, D'Ambrosi M, Mazzarella G, Varrella F, Vecchione R, Vegnente A. Early occurrence of hypertransaminasemia in a 13-month-old child with Wilson disease. *J Pediatr Gastroenterol Nutr*. 2003;36:637–8.
  17. Beyersdorff A, Findeisen A. Morbus Wilson: case report of a two-year-old child as first manifestation. *Scand J Gastroenterol*. 2006;41:496–7.
  18. Mak CM, Tam S, Fan ST, Liu CL, Lam CW. Wilson's disease: a patient undiagnosed for 18 years. *Hong Kong Med J*. 2006;12: 154–8.
  19. Lo Curto AG, Marchi A, Grasso M, Arbustini E, Loudianos G, Brega A. Early diagnosis of Wilson Disease in a six-year-old child. *J Pediatr*. 2006;148:141.
  20. Caprai S, Loudianos G, Massei F, Gori L, Lovicu M, Maggiore G. Direct diagnosis of Wilson disease by molecular genetics. *J Pediatr*. 2006;148:138–40.
  21. Kim JW, Kim JH, Seo JK, Ko JS, Chang JY, Yang HR, et al. Genetically confirmed Wilson disease in a 9-month old boy with elevations of aminotransferases. *World J Hepatol*. 2013;5: 156–9.
  22. Wiernicka A, Dądański M, Jańczyk W, Kamińska D, Naornia-kowska M, Hüsing-Kabar A, et al. Early onset of Wilson disease: diagnostic challenges. *J Pediatr Gastroenterol Nutr*. 2017;65:555–60.
  23. Wilson DC, Phillips MJ, Cox DW, Roberts EA. Severe hepatic Wilson's disease in preschool-aged children. *J Pediatr*. 2000; 137:719–22.
  24. Kalach N, Seidman EG, Morin C, Rasquin-Weber A, O'Regan S, Laberge JM, et al. Acute liver failure from Wilson's disease in a five-year-old child. *Can J Gastroenterol*. 1993;7:610–2.
  25. Ala A, Borjigin J, Rochwarger A, Schilsky M. Wilson disease in septuagenarian siblings: raising the bar for diagnosis. *Hepatology*. 2005;41:668–70.
  26. Perri RE, Hahn SH, Ferber MJ, Kamath PS. Wilson disease—keeping the bar for diagnosis raised. *Hepatology*. 2005;42:974.
  27. Członkowska A, Rodo M, Gromadzka G. Late onset Wilson's disease: therapeutic implications. *Mov Disord*. 2008;23:896–.
  28. Milkiewicz P, Saksena S, Hubscher SG, Elias E. Wilson's disease with superimposed autoimmune features: report of two cases and review. *J Gastroenterol Hepatol*. 2000;15:570–4.
  29. Dara N, Imanzadeh F, Sayyari AA, Nasri P, Hosseini AH. Simultaneous presentation of Wilson's disease and autoimmune hepatitis: a case report and review of literature. *Hepat Mon*. 2015;15:e29043.
  30. Ferenci P, Steindl-Munda P, Vogel W, Jessner W, Gschwantler M, Stauber R, et al. Diagnostic value of quantitative hepatic copper determination in patients with Wilson's disease. *Clin Gastroenterol Hepatol*. 2005;3:811–.
  31. Ferenci P. Phenotype-genotype correlations in patients with Wilson's disease. *Ann N Y Acad Sci*. 2014;1315:1–5.
  32. Taly AB, Meenakshi-Sundaram S, Sinha S, Swamy HS, Arunodaya GR. Wilson disease: description of 282 patients evaluated over 3 decades. *Medicine (Baltimore)*. 2007;86: 112–21.
  33. Soltanzadeh A, Soltanzadeh P, Nafissi S, Ghorbani A, Sikaroodi H, Lotfi J. Wilson's disease: a great masquerader. *Eur Neurol*. 2007;57:80–5.
  34. Machado A, Chien HF, Deguti MM, Cançado E, Azevedo RS, Scaff M, et al. Neurological manifestations in Wilson's disease: report of 119 cases. *Mov Disord*. 2006;21:2192–6.
  35. Starosta-Rubinstein S, Young AB, Kluin K, Hill G, Aisen AM, Gabrielsen T, et al. Clinical assessment of 31 patients with Wilson's disease. Correlations with structural changes on magnetic resonance imaging. *Arch Neurol*. 1987;44:365–70.
  36. Svetel M, Kozić D, Stefanova E, Semnic R, Dragašević N, Kostić VS. Dystonia in Wilson's disease. *Mov Disord*. 2001;16: 719–23.
  37. Jung KH, Ahn TB, Jeon BS. Wilson disease with an initial manifestation of polyneuropathy. *Arch Neurol*. 2005;62: 1628–31.
  38. Nasreddine ZS, Phillips NA, Bédirian V, Charbonneau S, Whitehead V, Collin I, et al. The Montreal Cognitive Assessment, MoCA: a brief screening tool for mild cognitive impairment. *J Am Geriatr Soc*. 2005;53:695–9.
  39. Leinweber B, Möller JC, Scherag A, Reuner U, Günther P, Lang CJG, et al. Evaluation of the Unified Wilson's Disease Rating Scale (UWDRS) in German patients with treated Wilson's disease. *Mov Disord*. 2008;23:54–62.
  40. Aggarwal A, Aggarwal N, Nagral A, Jankharia G, Bhatt M. A novel Global Assessment Scale for Wilson's disease (GAS for WD). *Mov Disord*. 2009;24:509–18.
  41. Akil M, Schwartz JA, Dutchak D, Yuzbasiyan-Gurkan V, Brewer GJ. The psychiatric presentations of Wilson's disease. *J Neuropsychiatry Clin Neurosci*. 1991;3:377–82.
  42. Svetel M, Potrebić A, Pekmezović T, Tomić A, Kresojević N, Ješić R, et al. Neuropsychiatric aspects of treated Wilson's disease. *Parkinsonism Relat Disord*. 2009;15:772–5.
  43. Zimbrea PC, Schilsky ML. Psychiatric aspects of Wilson disease: a review. *Gen Hosp Psychiatry*. 2014;36:53–62.
  44. Denning TR, Berrios GE. Wilson's disease. Psychiatric symptoms in 195 cases. *Arch Gen Psychiatry*. 1989;46:1126–34.
  45. Shanmugiah A, Sinha S, Taly AB, Prashanth LK, Tomar M, Arunodaya GR, et al. Psychiatric manifestations in Wilson's disease: a cross-sectional analysis. *J Neuropsychiatry Clin Neurosci*. 2008;20:81–5.
  46. Carta MG, Farina GC, Sorbello O, Moro MF, Demelia E, Cadoni F, et al. The risk of bipolar disorders and major depressive disorders in Wilson's disease: results of a case-control study (abstract). *Int Clin Psychopharmacol*. 2012;28:e61.
  47. Hesse S, Barthel H, Hermann W, Murai T, Kluge R, Wagner A, et al. Regional serotonin transporter availability and depression are correlated in Wilson's disease. *J Neural Transm (Vienna)*. 2003;110:923–33.
  48. Carta M, Mura G, Sorbello O, Farina G, Demelia L. Quality of life and psychiatric symptoms in Wilson's disease: the relevance of bipolar disorders. *Clin Pract Epidemiol Ment Health*. 2012;8:102–9.
  49. Oder W, Grimm G, Kollegger H, Ferenci P, Schneider B, Deecke L. Neurological and neuropsychiatric spectrum of Wilson's disease: a prospective study of 45 cases. *J Neurol*. 1991;238:281–7.
  50. Sagawa M, Takao M, Nogawa S, Mizuno M, Murata M, Amano T, et al. Wilson's disease associated with olfactory paranoid syndrome and idiopathic thrombocytopenic purpura. *No To Shinkei*. 2003;55:899–902.
  51. Chung YS, Ravi SD, Borge GF. Psychosis in Wilson's disease. *Psychosomatics*. 1986;27:65–.
  52. Shah N, Kumar D. Wilson's disease, psychosis, and ECT. *Convuls Ther*. 1997;13:278–9.
  53. Wichowicz HM, Cudała WJ, Sławek J. Wilson's disease associated with delusional disorder. *Psychiatry Clin Neurosci*. 2006;60:758–60.
  54. Huang CC, Chu NS. Wilson's disease: clinical analysis of 71 cases and comparison with previous Chinese series. *J Formos Med Assoc*. 1992;91:502–7.
  55. Cochen De Cock V, Girardot-Tinant N, Woimant F, Poujois A. Sleep abnormalities in Wilson's disease. *Curr Treat Options Neurol*. 2018;20:46.

56. Portala K, Westermark K, Ekselius L, Broman JE. Sleep in patients with treated Wilson's disease. A questionnaire study. *Nord J Psychiatry*. 2002;56:291–7.
57. Netto AB, Sinha S, Taly AB, Panda S, Rao S. Sleep in Wilson's disease: questionnaire based study. *Ann Indian Acad Neurol*. 2011;14:31–4.
58. Amann VC, Maru NK, Jain V. Hypersomnolence in Wilson disease. *J Clin Sleep Med*. 2015;11:1341–3.
59. Tribl GG, Trindade MC, Schredl M, Pires J, Reinhard I, Bittencourt T, et al. Dream recall frequencies and dream content in Wilson's disease with and without REM sleep behaviour disorder: a neurooneirologic study. *Behav Neurol*. 2016;2016:2983205.
60. Seniów J, Bak T, Gajda J, Poniatowska R, Członkowska A. Cognitive functioning in neurologically symptomatic and asymptomatic forms of Wilson's disease. *Mov Disord*. 2002;17:1077–83.
61. Frota NAF, Caramelli P, Barbosa ER. Cognitive impairment in Wilson's disease. *Dement Neuropsychol*. 2009;3:16–21.
62. Wenisch E, De Tassigny A, Trocello JM, Beretti J, Girardot-Tinant N, Woimant F. Cognitive profile in Wilson's disease: a case series of 31 patients. *Rev Neurol (Paris)*. 2013;169:944–9.
63. Han Y, Zhang F, Tian Y, Hu P, Li B, Wang K. Selective impairment of attentional networks of alerting in Wilson's disease. *PLoS One*. 2014;9:e100454.
64. Iwański S, Seniów J, Leśniak M, Litwin T, Członkowska A. Diverse attention deficits in patients with neurologically symptomatic and asymptomatic Wilson's disease. *Neuropsychology*. 2015;29:25–30.
65. Ma H, Lv X, Han Y, Zhang F, Ye R, Yu F, et al. Decision-making impairments in patients with Wilson's disease. *J Clin Exp Neuropsychol*. 2013;35:472–9.
66. Denning TR, Berrios GE. Wilson's disease: a longitudinal study of psychiatric symptoms. *Biol Psychiatry*. 1990;28:255–65.
67. Fleming CR, Dickson ER, Wahner HW, Hollenhorst RW, McCall JT. Pigmented corneal rings in non-Wilsonian liver disease. *Ann Intern Med*. 1977;86:285–8.
68. Frommer D, Morris J, Sherlock S, Abrams J, Newman S. Kayser-Fleischer-like rings in patients without Wilson's disease. *Gastroenterology*. 1977;72:1331–5.
69. Tauber J, Steinert RF. Pseudo-Kayser-Fleischer ring of the cornea associated with non-Wilsonian liver disease. A case report and literature review. *Cornea*. 1993;12:74–.
70. Dunn LL, Annable WL, Kliegman RM. Pigmented corneal rings in neonates with liver disease. *J Pediatr*. 1987;110:771–6.
71. Gow PJ, Smallwood RA, Angus PW, Smith AL, Wall AJ, Sewell RB. Diagnosis of Wilson's disease: an experience over three decades. *Gut*. 2000;46:415–9.
72. Emre S, Atillasoy EO, Ozdemir S, Schilsky M, Rathna Varma CV, Thung SN, et al. Orthotopic liver transplantation for Wilson's disease: a single-center experience. *Transplantation*. 2001;72:1232–6.
73. Medici V, Trevisan CP, D'Inca R, Barollo M, Zancan L, Fagioli S, et al. Diagnosis and management of Wilson's disease: results of a single center experience. *J Clin Gastroenterol*. 2006;40:936–41.
74. Merle U, Schaefer M, Ferenci P, Stremmel W. Clinical presentation, diagnosis and long-term outcome of Wilson's disease: a cohort study. *Gut*. 2007;56:115–20.
75. da Costa CM, Baldwin D, Portmann B, Lolin Y, Mowat AP, Mieli-Vergani G. Value of urinary copper excretion after penicillamine challenge in the diagnosis of Wilson's disease. *Hepatology*. 1992;15:609–15.
76. Giacchino R, Marazzi MG, Barabino A, Fasce L, Ciravegna B, Famularo L, et al. Syndromic variability of Wilson's disease in children. Clinical study of 44 cases. *Ital J Gastroenterol Hepatol*. 1997;29:155–61.
77. Sánchez-Albisua I, Garde T, Hierro L, Camarena C, Frauca F, de la Vega A, et al. A high index of suspicion: the key to an early diagnosis of Wilson's disease in childhood. *J Pediatr Gastroenterol Nutr*. 1999;28:186–90.
78. Demirkiran M, Jankovic J, Lewis RA, Cox DW. Neurologic presentation of Wilson disease without Kayser-Fleischer rings. *Neurology*. 1996;46:1040–3.
79. Sridhar MS, Rangaraju A, Anbarasu K, Reddy SP, Daga S, Jayalakshmi S, et al. Evaluation of Kayser-Fleischer ring in Wilson disease by anterior segment optical coherence tomography. *Indian J Ophthalmol*. 2017;65:354–7.
80. Sridhar MS. Advantages of anterior segment optical coherence tomography evaluation of the Kayser-Fleischer ring in Wilson disease. *Cornea*. 2017;36:343–6.
81. Rath A, Takkar B, Gaur N, Maharana PK. Optical coherence tomography of the Kayser-Fleischer ring: an ancillary diagnostic tool for Wilson's disease in children. *BMJ Case Rep*. 2017;2017:bcr2017220007.
82. Langwińska-Wośko E, Litwin T, Szulborski K, Członkowska A. Optical coherence tomography and electrophysiology of retinal and visual pathways in Wilson's disease. *Metab Brain Dis*. 2016;31:405–15.
83. Członkowska A, Litwin T, Dusek P, Ferenci P, Lutsenko S, Medici V, et al. Wilson disease. *Nat Rev Dis Primers*. 2018;4:21.
84. Telinius N, Ott P, Hjortdal J. Detection of Kayser-Fleischer ring using Scheimpflug imaging. *Acta Ophthalmol*. 2017;95:e248–9.
85. Ceresara G, Fogagnolo P, Zuin M, Zetelli S, Bovet J, Rossetti L. Study of corneal copper deposits in Wilson's disease by in vivo confocal microscopy. *Ophthalmologica*. 2014;231:147–52.
86. Cairns JE, Williams HP, Walshe JM. "Sunflower cataract" in Wilson's disease. *Br Med J*. 1969;3:95–6.
87. Langwińska-Wośko E, Litwin T, Dzieżyc K, Członkowska A. The sunflower cataract in Wilson's disease: pathognomonic sign or rare finding? *Acta Neurol Belg*. 2016;116:325–8.
88. Sturniolo GC, Lazzarini D, Bartolo O, Berton M, Leonardi A, Fregona IA, et al. Small fiber peripheral neuropathy in Wilson disease: an in vivo documentation by corneal confocal microscopy. *Invest Ophthalmol Vis Sci*. 2015;56:1390–5.
89. Walshe JM. The liver in Wilson's disease. In: Schiff L, Schiff ER, editors. *Diseases of the liver*. 6th ed. Philadelphia: J. B. Lippincott; 1987. p. 1037–50.
90. Dzieżyc-Jaworska K, Litwin T, Członkowska A. Clinical manifestations of Wilson disease in organs other than the liver and brain. *Ann Transl Med*. 2019;7:S62.
91. Fulop M, Sternlieb I, Scheinberg IH. Defective urinary acidification in Wilson's disease. *Ann Intern Med*. 1968;68:770–.
92. Chu CC, Huang CC, Chu NS. Recurrent hypokalemic muscle weakness as an initial manifestation of Wilson's disease. *Nephron*. 1996;73:477–9.
93. Azizi E, Eshel G, Aladjem M. Hypercalciuria and nephrolithiasis as a presenting sign in Wilson disease. *Eur J Pediatr*. 1989;148:548–9.
94. Nakada SY, Brown MR, Rabinowitz R. Wilson's disease presenting as symptomatic urolithiasis: a case report and review of the literature. *J Urol*. 1994;152:978–.
95. Di Stefano V, Lionetti E, Rotolo N, La Rosa M, Leonardi S. Hypercalciuria and nephrocalcinosis as early feature of Wilson disease onset: description of a pediatric case and literature review. *Hepat Mon*. 2012;12:e6233.
96. Golding DN, Walshe JM. Arthropathy of Wilson's disease. Study of clinical and radiological features in 32 patients. *Ann Rheum Dis*. 1977;36:99–111.
97. Quemeneur AS, Trocello JM, Ea HK, Ostertag A, Leyendecker A, Duclos-Vallée JC, et al. Bone status and fractures in 85 adults with Wilson's disease. *Osteoporos Int*. 2014;25:2573–80.
98. Weiss KH, Van de Moortele M, Gotthardt DN, Pfeifferberger J, Seeßle J, Ullrich E, et al. Bone demineralisation in a large

- cohort of Wilson disease patients. *J Inherit Metab Dis*. 2015;38:949–56.
99. Chenbhanich J, Thongprayoon C, Atsawarungruangkit A, Phupitakphol T, Cheungpasitporn W. Osteoporosis and bone mineral density in patients with Wilson's disease: a systematic review and meta-analysis. *Osteoporos Int*. 2018;29:315–22.
  100. Factor SM, Cho S, Sternlieb I, Scheinberg IH, Goldfischer S. The cardiomyopathy of Wilson's disease. Myocardial alterations in nine cases. *Virchows Arch A Pathol Anat Histol*. 1982;397:301–11.
  101. Hlubocká Z, Mareček Z, Linhart A, Kejřová E, Pospíšilová L, Martásek P, et al. Cardiac involvement in Wilson disease. *J Inherit Metab Dis*. 2002;25:269–77.
  102. Grandis DJ, Nah G, Whitman IR, Vittinghoff E, Dewland TA, Olgin JE, et al. Wilson's disease and cardiac myopathy. *Am J Cardiol*. 2017;120:2056–60.
  103. Buksińska-Lisik M, Litwin T, Pasierski T, Członkowska A. Cardiac assessment in Wilson's disease patients based on electrocardiography and echocardiography examination. *Arch Med Sci*. 2019;15:857–64.
  104. Kuan P. Cardiac Wilson's disease. *Chest*. 1987;91:579–83.
  105. Chu EC, Chu NS, Huang CC. Autonomic involvement in Wilson's disease: a study of sympathetic skin response and RR interval variation. *J Neurol Sci*. 1997;149:131–7.
  106. Bhattacharya K, Velickovic M, Schilsky M, Kaufmann H. Autonomic cardiovascular reflexes in Wilson's disease. *Clin Auton Res*. 2002;12:190–2.
  107. Meenakshi-Sundaram S, Taly AB, Kamath V, Arunodaya GR, Rao S, Swamy HS. Autonomic dysfunction in Wilson's disease—a clinical and electrophysiological study. *Clin Auton Res*. 2002;12:185–9.
  108. Carpenter TO, Carnes DL Jr, Anast CS. Hypoparathyroidism in Wilson's disease. *N Engl J Med*. 1983;309:873–7.
  109. Walshe JM. Pregnancy in Wilson's disease. *QJM*. 1977;46:73–83.
  110. Klee JG. Undiagnosed Wilson's disease as cause of unexplained miscarriage. *Lancet*. 1979;2:423.
  111. Kaushansky A, Frydman M, Kaufman H, Homburg R. Endocrine studies of the ovulatory disturbances in Wilson's disease (hepatolenticular degeneration). *Fertil Steril*. 1987;47:270–3.
  112. Tamacka B, Rodo M, Cichy S, Członkowska A. Procreation ability in Wilson's disease. *Acta Neurol Scand*. 2000;101:395–8.
  113. Weizman Z, Picard E, Barki Y, Moses S. Wilson's disease associated with pancreatitis. *J Pediatr Gastroenterol Nutr*. 1988;7:931–3.
  114. Fleischer B. Ueber eine der "Pseudosclerose" nahestehende bisher unbekannte Krankheit (gekennzeichnet durch Tremor, psychische Störungen, braeunliche Pigmentierung bestimmter Gewebe, insbesondere auch der Hornhautperipherie, Lebercirrhose). *Deutsch Z Nervenheilk*. 1912;44:179–201.
  115. Scheinberg IH, Gitlin D. Deficiency of ceruloplasmin in patients with hepatolenticular degeneration (Wilson's disease). *Science*. 1952;116:484–5.
  116. Sternlieb I. Perspectives on Wilson's disease. *Hepatology*. 1990;12:1234–9.
  117. Ferenci P, Caca K, Loudianos G, Mieli-Vergani G, Tanner S, Sternlieb I, et al. Diagnosis and phenotypic classification of Wilson disease. *Liver Int*. 2003;23:139–42.
  118. McIntyre N, Clink HM, Levi AJ, Cumings JN, Sherlock S. Hemolytic anemia in Wilson's disease. *N Engl J Med*. 1967;276:439–4.
  119. Shaver WA, Bhatt H, Combes B. Low serum alkaline phosphatase activity in Wilson's disease. *Hepatology*. 1986;6:859–63.
  120. Camarata MA, Gottfried M, Rule JA, Ala A, Lee WM, Stravitz RT, et al. Outcomes of acute liver injury in adults due to Wilson's disease: is survival without transplant possible? *Liver Transpl*. 2020;26:330–6.
  121. Agrawal AK, Haddad FG, Matsunaga A. Acute nonimmune hemolytic anemia without fulminant hepatitis in Wilson disease. *J Pediatr Hematol Oncol*. 2011;33:e163–5.
  122. Shiva S, Wang X, Ringwood LA, Xu X, Yuditskaya S, Annavajhala V, et al. Ceruloplasmin is a NO oxidase and nitrite synthase that determines endocrine NO homeostasis. *Nat Chem Biol*. 2006;2:486–93.
  123. Morell AG, Windsor J, Sternlieb I, Scheinberg IH. Measurement of the concentration of ceruloplasmin by determination of its oxidase activity. In: Sunderman SW, Sunderman SW Jr, editors. *Laboratory diagnosis of liver diseases*. St. Louis: Warren H. Green; 1968. p. 193–5.
  124. Schosinsky KH, Lehmann HP, Beeler MS. Measurement of ceruloplasmin from its oxidase activity in serum by use of o-dianisidine dihydrochloride. *Clin Chem*. 1974;20:1556–63.
  125. Erel O. Automated measurement of serum ferroxidase activity. *Clin Chem*. 1998;44:2313–9.
  126. Gnanou JV, Thykadavil VG, Thuppil V. Pros and cons of immunochemical and enzymatic method in the diagnosis of Wilson's disease. *Indian J Med Sci*. 2006;60:371–5.
  127. Solov'yev N, Ala A, Schilsky M, Mills C, Willis K, Harrington CF. Biomedical copper speciation in relation to Wilson's disease using strong anion exchange chromatography coupled to triple quadrupole inductively coupled plasma mass spectrometry. *Anal Chim Acta*. 2020;1098:27–36.
  128. Mezaki T, Matsumoto S, Hamada C, Mukoyama I, Sakamoto T, Mizutani K, et al. Decreased serum ceruloplasmin and copper levels in cervical dystonia. *Ann Neurol*. 2001;49:138–9.
  129. Fuhrman MP, Herrmann V, Masidonski P, Eby C. Pancytopenia after removal of copper from total parenteral nutrition. *J Parenter Enter Nutr*. 2001;24:361–6.
  130. Kumar N, McEvoy KM, Ahlskog JE. Myelopathy due to copper deficiency following gastrointestinal surgery. *Arch Neurol*. 2003;60:1782–5.
  131. Menkes JH. Menkes disease and Wilson disease: two sides of the same copper coin. Part I: Menkes disease. *Eur J Paediatr Neurol*. 1999;3:147–58.
  132. Cauza E, Maier-Dobersberger T, Polli C, Kaserer K, Kramer L, Ferenci P. Screening for Wilson's disease in patients with liver diseases by serum ceruloplasmin. *J Hepatol*. 1997;27:358–62.
  133. Perman JA, Werlin SL, Grand RJ, Watkins JB. Laboratory measures of copper metabolism in the differentiation of chronic active hepatitis and Wilson disease in children. *J Pediatr*. 1979;94:564–8.
  134. Scheinberg IH, Sternlieb I. *Wilson's disease*. Philadelphia: W. B. Saunders; 1984.
  135. Walshe JM. Wilson's disease presenting with features of hepatic dysfunction: a clinical analysis of eighty-seven patients. *Q J Med*. 1989;70:253–63.
  136. Lau JY, Lai CL, Wu PC, Pan HY, Lin HJ, Todd D. Wilson's disease: 35 years' experience. *Q J Med*. 1990;75:597–605.
  137. Mak CM, Lam CW, Tam S. Diagnostic accuracy of serum ceruloplasmin in Wilson disease: determination of sensitivity and specificity by ROC curve analysis among *ATP7B*-genotyped subjects. *Clin Chem*. 2008;54:1356–62.
  138. Wilson DM, Goldstein NP. Renal urate excretion in patients with Wilson's disease. *Kidney Int*. 1973;4:331–6.
  139. Stremmel W, Meyerrose KW, Niederau C, Hefter H, Kreuzpaintner G, Strohmeyer G. Wilson disease: clinical presentation, treatment, and survival. *Ann Intern Med*. 1991;115:720–6.
  140. Roberts EA, Cox DW. Wilson disease. *Baillieres Clin Gastroenterol*. 1998;12:237–56.
  141. Gaffney D, Fell GS, O'Reilly DS. ACP Best Practice No 163. Wilson's disease: acute and presymptomatic laboratory diagnosis and monitoring. *J Clin Pathol*. 2000;53:807–12.

142. LaRusso NF, Summerskill WH, McCall JT. Abnormalities of chemical tests for copper metabolism in chronic active liver disease: differentiation from Wilson's disease. *Gastroenterology*. 1976;70:653–5.
143. Guillaud O, Brunet AS, Mallet I, Dumortier J, Pelosse M, Heissat S, et al. Relative exchangeable copper: a valuable tool for the diagnosis of Wilson disease. *Liver Int*. 2018;38:350–7.
144. Gross JB Jr, Ludwig J, Wiesner RH, McCall JT, LaRusso NF. Abnormalities in tests of copper metabolism in primary sclerosing cholangitis. *Gastroenterology*. 1985;89:272–8.
145. Korman JD, Volenberg I, Balko J, Webster J, Schiodt FV, Squires HR Jr, et al. Screening for Wilson disease in acute liver failure: a comparison of currently available diagnostic tests. *Hepatology*. 2008;48:1167–74.
146. Duncan A, Yacoubian C, Beetham R, Catchpole A, Bullock D. The role of calculated non-caeruloplasmin-bound copper in Wilson's disease. *Ann Clin Biochem*. 2017;54:649–54.
147. McMillin GA, Travis JJ, Hunt JW. Direct measurement of free copper in serum or plasma ultrafiltrate. *Am J Clin Pathol*. 2009;131:160–5.
148. El Balkhi S, Trocello JM, Poupon J, Chappuis P, Massicot F, Girardot-Tinant N, et al. Relative exchangeable copper: a new highly sensitive and highly specific biomarker for Wilson's disease diagnosis. *Clin Chim Acta*. 2011;412:2254–60.
149. Poujois A, Trocello JM, Djebani-Oussedik N, Poupon J, Collet C, Girardot-Tinant N, et al. Exchangeable copper: a reflection of the neurological severity in Wilson's disease. *Eur J Neurol*. 2017;24:154–60.
150. Trocello JM, El Balkhi S, Woimant F, Girardot-Tinant N, Chappuis P, Lloyd C, et al. Relative exchangeable copper: a promising tool for family screening in Wilson disease. *Mov Disord*. 2014;29:558–62.
151. Tu JB, Blackwell RQ. Studies on levels of penicillamine-induced cupriuresis in heterozygotes of Wilson's disease. *Metabolism*. 1967;16:507–13.
152. García-Villarreal L, Daniels S, Shaw SH, Cotton D, Galvin M, Geskes J, et al. High prevalence of the very rare Wilson disease gene mutation Leu708Pro in the Island of Gran Canaria (Canary Islands, Spain): a genetic and clinical study. *Hepatology*. 2000;32:1329–36.
153. Roberts EA, Jimenez C, O'Connor C, Cox DW. Diagnosis and outcome of Wilson disease in a paediatric cohort (abstract). *J Pediatr Gastroenterol Nutr*. 2004;39(Suppl 1):A128.
154. Nicastro E, Ranucci G, Vajro P, Vegnente A, Iorio R. Re-evaluation of the diagnostic criteria for Wilson disease in children with mild liver disease. *Hepatology*. 2010;52:1948–56.
155. Frommer DJ. Urinary copper excretion and hepatic copper concentrations in liver disease. *Digestion*. 1981;21:169–78.
156. Sood V, Rawat D, Khanna R, Alam S. Cholestatic liver disease masquerading as Wilson disease. *Indian J Gastroenterol*. 2015;34:174–7.
157. Anheim M, Chamouard P, Rudolf G, Ellero B, Vercueil L, Goichot B, et al. Unexpected combination of inherited chorea-acanthocytosis with MDR3 (ABCB4) defect mimicking Wilson's disease. *Clin Genet*. 2010;78:294–5.
158. Shneider BL. ABCB4 disease presenting with cirrhosis and copper overload—potential confusion with Wilson disease. *J Clin Exp Hepatol*. 2011;1:115–7.
159. Ramraj R, Finegold MJ, Karpen SJ. Progressive familial intrahepatic cholestasis type 3: overlapping presentation with Wilson disease. *Clin Pediatr (Phila)*. 2012;51:689–91.
160. Boga S, Jain D, Schilsky ML. Presentation of progressive familial intrahepatic cholestasis type 3 mimicking Wilson disease: molecular genetic diagnosis and response to treatment. *Pediatr Gastroenterol Hepatol Nutr*. 2015;18:202–8.
161. Khan S, Schilsky M, Silber G, Morgenstern B, Miloh T. The challenges of diagnosing and following Wilson disease in the presence of proteinuria. *Pediatr Gastroenterol Hepatol Nutr*. 2016;19:139–42.
162. Vieira J, Oliveira PV, Juliano Y, Warde KRJ, Deguti MM, Barbosa ER, et al. Urinary copper excretion before and after oral intake of D-penicillamine in parents of patients with Wilson's disease. *Dig Liver Dis*. 2012;44:323–7.
163. Müller T, Koppikar S, Taylor RM, Carragher F, Schlenck B, Heinz-Erian P, et al. Re-evaluation of the penicillamine challenge test in the diagnosis of Wilson's disease in children. *J Hepatol*. 2007;47:270–6.
164. Dhawan A, Taylor RM, Cheeseman P, De Silva P, Katsiyianakis L, Mieli-Vergani G. Wilson's disease in children: 37-year experience and revised King's score for liver transplantation. *Liver Transpl*. 2005;11:441–8.
165. Członkowska A, Rodo M, Wierzchowska-Ciok A, Smolinski L, Litwin T. Accuracy of the radioactive copper incorporation test in the diagnosis of Wilson disease. *Liver Int*. 2018;38:1860–6.
166. Lyon TD, Fell GS, Gaffney D, McGaw BA, Russell RI, Park RH, et al. Use of a stable copper isotope ( $^{65}\text{Cu}$ ) in the differential diagnosis of Wilson's disease. *Clin Sci*. 1995;88:727–32.
167. Costas-Rodríguez M, Delanghe J, Vanhaecke F. High-precision isotopic analysis of essential mineral elements in biomedicine: natural isotope ratio variations as potential diagnostic and/or prognostic markers. *Trends Anal Chem*. 2016;76:182–93.
168. Cope-Yokoyama S, Finegold MJ, Sturniolo GC, Kim K, Mescoli C, Rugge M, et al. Wilson disease: histopathological correlations with treatment on follow-up liver biopsies. *World J Gastroenterol*. 2010;16:1487–94.
169. Stromeyer FW, Ishak KG. Histology of the liver in Wilson's disease: a study of 34 cases. *Am J Clin Pathol*. 1980;73:12–24.
170. Johncilla M, Mitchell KA. Pathology of the liver in copper overload. *Semin Liver Dis*. 2011;31:239–44.
171. Lackner C, Denk H. Histopathology of Wilson disease. In: Kerker N, Roberts EA, editors. *Clinical and translational perspectives on Wilson disease*. London: Academic Press; 2018. p. 257–70.
172. Strand S, Hofmann WJ, Grambihler A, Hug H, Volkmann M, Otto G, et al. Hepatic failure and liver cell damage in acute Wilson's disease involve CD95 (APO-1/Fas) mediated apoptosis. *Nat Med*. 1998;4:588–93.
173. Goldfischer S, Sternlieb I. Changes in the distribution of hepatic copper in relation to the progression of Wilson's disease (hepatolenticular degeneration). *Am J Pathol*. 1968;53:883–901.
174. Pilloni L, Lecca S, Van Eyken P, Flore C, Demelia L, Pilleri G, et al. Value of histochemical stains for copper in the diagnosis of Wilson's disease. *Histopathology*. 1998;33:28–33.
175. Sternlieb I. Mitochondrial and fatty changes in hepatocytes of patients with Wilson's disease. *Gastroenterology*. 1968;55:354–67.
176. Alqahtani SA, Chami R, Abuquteish D, Vandriel SM, Yap C, Kukkadi L, et al. Hepatic ultrastructural features distinguish paediatric Wilson disease from NAFLD and autoimmune hepatitis. *Liver Int*. 2022;42:2482–91.
177. Phillips MJ, Poucell S, Patterson J, Valencia P. *The liver: an atlas and text of ultrastructural pathology*. New York: Raven Press; 1987.
178. Yang X, Tang XP, Zhang YH, Luo KZ, Jiang YF, Lei JH, et al. Prospective evaluation of the diagnostic accuracy of hepatic copper content, as determined using the entire core of a liver biopsy sample. *Hepatology*. 2015;62:1731–41.
179. Ludwig J, Moyer TP, Rakela J. The liver biopsy diagnosis of Wilson's disease. *Methods in pathology*. *Am J Clin Pathol*. 1994;102:443–6.
180. Mounajjed T, Oxentenko AS, Qureshi H, Smyrk T. Revisiting the topic of histochemically detectable copper in various liver

- diseases with special focus on venous outflow impairment. *Am J Clin Pathol.* 2013;139:79–86.
181. Pandit A, Bhawe S. Present interpretation of the role of copper in Indian childhood cirrhosis. *Am J Clin Nutr.* 1996;63:830S–5S.
  182. Tanner MS. Indian childhood cirrhosis and Tyrolean childhood cirrhosis. Disorders of a copper transport gene? *Adv Exp Med Biol.* 1999;448:127–37.
  183. Liggi M, Mais C, Demurtas M, Sorbello O, Demelia E, Civolani A, et al. Uneven distribution of hepatic copper concentration and diagnostic value of double-sample biopsy in Wilson's disease. *Scand J Gastroenterol.* 2013;48:1452–8.
  184. Duncan A, Harrington CF, Catchpole A, Taylor A. Is the measurement of copper and iron in liver biopsies reliable? Results from a pilot external quality assurance scheme. *J Trace Elem Med Biol.* 2019;52:288–92.
  185. Sintusek P, Dhawan A. Liver copper estimation: does liver biopsy size really matter? *Hepatology.* 2016;64:1381–2.
  186. Song YM, Chen MD. A single determination of liver copper concentration may misdiagnose Wilson's disease. *Clin Biochem.* 2000;33:589–90.
  187. Boaru SG, Merle U, Uerlings R, Zimmermann A, Flechtenmacher C, Willheim C, et al. Laser ablation inductively coupled plasma mass spectrometry imaging of metals in experimental and clinical Wilson's disease. *J Cell Mol Med.* 2015;19:806–14.
  188. Hachmöller O, Aichler M, Schwamborn K, Lutz L, Werner M, Sperling M, et al. Element bioimaging of liver needle biopsy specimens from patients with Wilson's disease by laser ablation-inductively coupled plasma-mass spectrometry. *J Trace Elem Med Biol.* 2016;35:97–102.
  189. Prashanth LK, Sinha S, Taly AB, Vasudev MK. Do MRI features distinguish Wilson's disease from other early onset extrapyramidal disorders? An analysis of 100 cases. *Mov Disord.* 2010;25:672–8.
  190. Sinha S, Taly AB, Prashanth LK, Ravishankar S, Arunodaya GR, Vasudev MK. Sequential MRI changes in Wilson's disease with de-coppering therapy: a study of 50 patients. *Br J Radiol.* 2007;80:744–9.
  191. Aisen AM, Martel W, Gabrielsen TO, Glazer GM, Brewer G, Young AB, et al. Wilson disease of the brain: MR imaging. *Radiology.* 1985;157:137–41.
  192. van Wassenaeer-van Hall HN, van den Heuvel AG, Algra A, Hoogenraad TU, Mali WP. Wilson disease: findings at MR imaging and CT of the brain with clinical correlation. *Radiology.* 1996;198:531–6.
  193. Gao J, Brackley S, Mann JP. The global prevalence of Wilson disease from next-generation sequencing data. *Genet Med.* 2019;21:1155–63.
  194. Loudianos G, Dessi V, Lovicu M, Angius A, Figus A, Lilliu F, et al. Molecular characterization of Wilson disease in the Sardinian population—evidence of a founder effect. *Hum Mutat.* 1999;14:294–303.
  195. Thomas GR, Jensson O, Gudmundsson G, Thorsteinsson L, Cox DW. Wilson disease in Iceland: a clinical and genetic study. *Am J Hum Genet.* 1995;56:1140–6.
  196. Kim EK, Yoo OJ, Song KY, Yoo HW, Choi SY, Cho SW, et al. Identification of three novel mutations and a high frequency of the Arg778Leu mutation in Korean patients with Wilson disease. *Hum Mutat.* 1998;11:275–8.
  197. Nanji MS, Nguyen VTT, Kawasoe JH, Inui K, Endo F, Nakajima T, et al. Haplotype and mutation analysis in Japanese patients with Wilson disease. *Am J Hum Genet.* 1997;60:1423–9.
  198. Wan L, Tsai CH, Tsai Y, Hsu CM, Lee CC, Tsai FJ. Mutation analysis of Taiwanese Wilson disease patients. *Biochem Biophys Res Commun.* 2006;345:734–8.
  199. Margarit E, Bach V, Gómez D, Bruguera M, Jara P, Queralt R, et al. Mutation analysis of Wilson disease in the Spanish population — identification of a prevalent substitution and eight novel mutations in the ATP7B gene. *Clin Genet.* 2005;68:61–8.
  200. Caca K, Ferenci P, Kühn HJ, Polli C, Willgerodt H, Kunath B, et al. High prevalence of the H1069Q mutation in East German patients with Wilson disease: rapid detection of mutations by limited sequencing and phenotype-genotype analysis. *J Hepatol.* 2001;35:575–81.
  201. Firneisz G, Lakatos PL, Szalay F, Polli C, Glant TT, Ferenci P. Common mutations of ATP7B in Wilson disease patients from Hungary. *Am J Med Genet.* 2002;108:23–8.
  202. Ferenci P, Stremmel W, Członkowska A, Szalay F, Viveiros A, Stättermayer AF, et al. Age and sex but not ATP7B genotype effectively influence the clinical phenotype of Wilson disease. *Hepatology.* 2019;69:1464–76.
  203. Poon KS, Tan KML, Koay ESC. Targeted next-generation sequencing of the ATP7B gene for molecular diagnosis of Wilson disease. *Clin Biochem.* 2016;49:166–71.
  204. Mameli E, Lepori MB, Chiappe F, Ranucci G, Di Dato F, Iorio R, et al. Wilson's disease caused by alternative splicing and Alu exonization due to a homozygous 3039-bp deletion spanning from intron 1 to exon 2 of the ATP7B gene. *Gene.* 2015;569:276–9.
  205. Thomas GR, Forbes JR, Roberts EA, Walshe JM, Cox DW. The Wilson disease gene: spectrum of mutations and their consequences. *Nat Genet.* 1995;9:210–7.
  206. Merle U, Weiss KH, Eisenbach C, Tuma S, Ferenci P, Stremmel W. Truncating mutations in the Wilson disease gene ATP7B are associated with very low serum ceruloplasmin oxidase activity and an early onset of Wilson disease. *BMC Gastroenterol.* 2010;10:8.
  207. Okada T, Shiono Y, Kaneko Y, Miwa K, Hasatani K, Hayashi Y, et al. High prevalence of fulminant hepatic failure among patients with mutant alleles for truncation of ATP7B in Wilson's disease. *Scand J Gastroenterol.* 2010;45:1232–7.
  208. Hua R, Hua F, Jiao Y, Pan Y, Yang X, Peng S, et al. Mutational analysis of ATP7B in Chinese Wilson disease patients. *Am J Transl Res.* 2016;8:2851–61.
  209. Ferenci P, Roberts EA. Defining Wilson disease phenotypes: from the patient to the bench and back again. *Gastroenterology.* 2012;142:692–.
  210. Medici V, Shibata NM, Kharbanda KK, LaSalle JM, Woods R, Liu S, et al. Wilson's disease: changes in methionine metabolism and inflammation affect global DNA methylation in early liver disease. *Hepatology.* 2013;57:555–65.
  211. Mordaunt CE, Shibata NM, Kieffer DA, Członkowska A, Litwin T, Weiss KH, et al. Epigenetic changes of the thioredoxin system in the tx-j mouse model and in patients with Wilson disease. *Hum Mol Genet.* 2018;27:3854–69.
  212. Schiefermeier M, Kollegger H, Madl C, Polli C, Oder W, Kühn HJ, et al. The impact of apolipoprotein E genotypes on age at onset of symptoms and phenotypic expression in Wilson's disease. *Brain.* 2000;123:585–90.
  213. Ferenci P, Pfeifferberger J, Stättermayer AF, Stauber RE, Willheim C, Weiss KH, et al. HSD17B13 truncated variant is associated with a mild hepatic phenotype in Wilson's disease. *JHEP Rep.* 2019;1:2–8.
  214. Houwen RH, Roberts EA, Thomas GR, Cox DW. DNA markers for the diagnosis of Wilson disease. *J Hepatol.* 1993;17:269–76.
  215. Yener S, Akarsu M, Karacanci C, Sengul B, Topalak O, Biberoglu K, et al. Wilson's disease with coexisting autoimmune hepatitis. *J Gastroenterol Hepatol.* 2004;19:114–6.
  216. Aigner E, Strasser M, Haufe H, Sonnweber T, Hohla F, Stadlmayr A, et al. A role for low hepatic copper concentrations in nonalcoholic fatty liver disease. *Am J Gastroenterol.* 2010;105:1978–85.
  217. Stättermayer AF, Traussnigg S, Aigner E, Kienbacher C, Huber-Schönauer U, Steindl-Munda P, et al. Low hepatic copper content and PNPLA3 polymorphism in non-alcoholic



- fatty liver disease in patients without metabolic syndrome. *J Trace Elem Med Biol.* 2017;39:100–7.
218. Liggi M, Murgia D, Civolani A, Demelia E, Sorbello O, Demelia L. The relationship between copper and steatosis in Wilson's disease. *Clin Res Hepatol Gastroenterol.* 2013;37:36–40.
  219. Nobili V, Siotto M, Bedogni G, Ravà L, Pietrobattista A, Panera N, et al. Levels of serum ceruloplasmin associate with pediatric nonalcoholic fatty liver disease. *J Pediatr Gastroenterol Nutr.* 2013;56:370–5.
  220. Gitlin JD. Aceruloplasminemia. *Pediatr Res.* 1998;44:271–6.
  221. Marchi G, Busti F, Lira Zidanes A, Castagna A, Girelli D. Aceruloplasminemia: a severe neurodegenerative disorder deserving an early diagnosis. *Front Neurosci.* 2019;13:325.
  222. Harris ZL, Klomp LW, Gitlin JD. Aceruloplasminemia: an inherited neurodegenerative disease with impairment of iron homeostasis. *Am J Clin Nutr.* 1998;67(5 Suppl):972S–7S.
  223. Gubler CJ, Lahey ME, Chase MS, Cartwright GE, Wintrobe MM. Studies on copper metabolism. III. The metabolism of iron in copper deficient swine. *Blood.* 1952;7:1075–92.
  224. Chase MS, Gubler CJ, Cartwright GE, Wintrobe MM. Studies on copper metabolism. V. Storage of iron in liver of copper-deficient rats. *Proc Soc Exp Biol Med.* 1952;80:749–51.
  225. Harris ZL, Durley AP, Man TK, Gitlin JD. Targeted gene disruption reveals an essential role for ceruloplasmin in cellular iron efflux. *Proc Natl Acad Sci U S A.* 1999;96:10812–7.
  226. Kerkhof M, Honkoop P. Never forget aceruloplasminemia in case of highly suggestive Wilson's disease score. *Hepatology.* 2014;59:1645–7.
  227. Socha P, Vajro P, Lefeber D, Adamowicz M, Tanner S. Search for rare liver diseases: the case of glycosylation defects mimicking Wilson disease. *Clin Res Hepatol Gastroenterol.* 2014;38:403–6.
  228. Tegtmeyer LC, Rust S, van Scherpenzeel M, Ng BG, Losfeld ME, Timal S, et al. Multiple phenotypes in phosphoglucomutase 1 deficiency. *N Engl J Med.* 2014;370:533–42.
  229. Jansen JC, Cirak S, van Scherpenzeel M, Timal S, Reunert J, Rust S, et al. CCDC115 deficiency causes a disorder of Golgi homeostasis with abnormal protein glycosylation. *Am J Hum Genet.* 2016;98:310–21.
  230. Girard M, Poujois A, Fabre M, Lacaille F, Debray D, Rio M, et al. CCDC115-CDG: a new rare and misleading inherited cause of liver disease. *Mol Genet Metab.* 2018;124:228–35.
  231. Jansen JC, Timal S, van Scherpenzeel M, Michelakakis H, Vicogne D, Ashikov A, et al. TMEM199 deficiency is a disorder of Golgi homeostasis characterized by elevated aminotransferases, alkaline phosphatase, and cholesterol and abnormal glycosylation. *Am J Hum Genet.* 2016;98:322–0.
  232. Roche-Sicot J, Benhamou JP. Acute intravascular hemolysis and acute liver failure associated as a first manifestation of Wilson's disease. *Ann Intern Med.* 1977;86:301–.
  233. Hamlyn AN, Gollan JL, Douglas AP, Sherlock S. Fulminant Wilson's disease with haemolysis and renal failure: copper studies and assessment of dialysis regimens. *Br Med J.* 1977;2:660–2.
  234. McCullough AJ, Fleming CR, Thistle JL, Baldus WP, Ludwig J, McCall JT, et al. Diagnosis of Wilson's disease presenting as fulminant hepatic failure. *Gastroenterology.* 1983;84:161–7.
  235. Ferlan-Marolt V, Stepec S. Fulminant Wilsonian hepatitis unmasked by disease progression: report of a case and review of the literature. *Dig Dis Sci.* 1999;44:1054–8.
  236. Vandriel SM, Ayoub MD, Ricciuto A, Hansen BE, Ling SC, Ng VL, et al. Pediatric Wilson disease presenting as acute liver failure: an individual patient data meta-analysis. *J Pediatr Gastroenterol Nutr.* 2020;71:e90–6.
  237. Schilsky ML, Scheinberg IH, Sternlieb I. Liver transplantation for Wilson's disease: indications and outcome. *Hepatology.* 1994;19:583–7.
  238. Alam S, Lal BB, Sood V, Khanna R, Kumar G. AARC-ACLF score: best predictor of outcome in children and adolescents with decompensated Wilson disease. *Hepatol Int.* 2019;13:330–8.
  239. Zandman-Goddard G, Weiss P, Avidan B, Bar-Meir S, Shoenfeld Y. Acute varicella infection heralding Wilsonian crisis. *J Clin Gastroenterol.* 1994;18:265–6.
  240. Sallie R, Chiyende J, Tan KC, Bradley D, Portmann B, Williams R, et al. Fulminant hepatic failure resulting from coexistent Wilson's disease and hepatitis E. *Gut.* 1994;35:849–53.
  241. Lembowicz K, Kryczka W, Walewska-Zielecka B, Kubicka J. Wilson's disease coexisting with viral hepatitis type C: a case report with histological and ultrastructural studies of the liver. *Ultrastruct Pathol.* 1999;23:39–44.
  242. Xuan A, Bookman I, Cox DW, Heathcote J. Three atypical cases of Wilson disease: assessment of the Leipzig scoring system in making a diagnosis. *J Hepatol.* 2007;47:428–33.
  243. Tatsumi Y, Shinohara T, Imoto M, Wakusawa S, Yano M, Hayashi K, et al. Potential of the international scoring system for the diagnosis of Wilson disease to differentiate Japanese patients who need anti-copper treatment. *Hepatol Res.* 2011;41:887–96.
  244. Gancheva D, Kotzev I, Kaneva M. Evaluation of some parameters of copper metabolism and Leipzig scoring system in the diagnosis of Wilson disease. *Scripta Sci Med.* 2014;46:47–53.
  245. Koppikar S, Dhawan A. Evaluation of the scoring system for the diagnosis of Wilson's disease in children. *Liver Int.* 2005;25:680–1.
  246. Sintusek P, Kyrana E, Dhawan A. Value of serum zinc in diagnosing and assessing severity of liver disease in children with Wilson disease. *J Pediatr Gastroenterol Nutr.* 2018;67:377–82.
  247. Tissières P, Chevret L, Debray D, Devictor D. Fulminant Wilson's disease in children: appraisal of a critical diagnosis. *Pediatr Crit Care Med.* 2003;4:338–43.
  248. Nazer H, Ede RJ, Mowat AP, Williams R. Wilson's disease: clinical presentation and use of prognostic index. *Gut.* 1986;27:1377–81.
  249. Petrasek J, Jirsa M, Sperl J, Kozak L, Taimr P, Spicak J, et al. Revised King's College score for liver transplantation in adult patients with Wilson's disease. *Liver Transpl.* 2007;13:55–61.
  250. Fischer RT, Soltys KA, Squires RH Jr, Jaffe R, Mazariegos GV, Schneider BL. Prognostic scoring indices in Wilson disease: a case series and cautionary tale. *J Pediatr Gastroenterol Nutr.* 2011;52:466–9.
  251. Devarbavi H, Singh R, Adarsh CK, Sheth K, Kiran R, Patil M. Factors that predict mortality in children with Wilson disease associated acute liver failure and comparison of Wilson disease specific prognostic indices. *J Gastroenterol Hepatol.* 2014;29:380–6.
  252. Choudhury A, Jindal A, Maiwall R, Sharma MK, Sharma BC, Pamecha V, et al. Liver failure determines the outcome in patients of acute-on-chronic liver failure (ACLF): comparison of APASL ACLF Research Consortium (AARC) and CLIF-SOFA models. *Hepatol Int.* 2017;11:461–71.
  253. Owada M, Suzuki K, Fukushima M, Yamauchi K, Kitagawa T. Mass screening for Wilson's disease by measuring urinary holoceruloplasmin. *J Pediatr.* 2002;140:614–.
  254. Aoki K. Newborn screening in Japan. *Southeast Asian J Trop Med Public Health.* 2003;34(Suppl 3):80–4.
  255. Kroll CA, Ferber MJ, Dawson BD, Jacobson RM, Mensink KA, Lorey F, et al. Retrospective determination of ceruloplasmin in newborn screening blood spots of patients with Wilson disease. *Mol Genet Metab.* 2006;89:134–8.
  256. Collins CJ, Yi F, Dayuha R, Duong P, Horslen S, Camarata M, et al. Direct measurement of ATP7B peptides is highly effective

- in the diagnosis of Wilson disease. *Gastroenterology*. 2021; 160:2367–82.
257. Cossu P, Pirastu M, Nucaro A, Figus A, Balestrieri A, Borroni C, et al. Prenatal diagnosis of Wilson's disease by analysis of DNA polymorphism. *N Engl J Med*. 1992;327:57.
  258. Loudianos G, Figus AL, Loi A, Angius A, Dessi V, Deiana M, et al. Improvement of prenatal diagnosis of Wilson disease using microsatellite markers. *Prenat Diagn*. 1994;14:999–1002.
  259. Yamaguchi Y, Aoki T, Arashima S, Ooura T, Takada G, Kitagawa T, et al. Mass screening for Wilson's disease: results and recommendations. *Pediatr Int*. 1999;41:405–8.
  260. Valentino PL, Roberts EA, Beer S, Miloh T, Arnon R, Vittorio JM, et al. Management of Wilson disease diagnosed in infancy: an appraisal of available experience to generate discussion. *J Pediatr Gastroenterol Nutr*. 2020;70:547–.
  261. Sternlieb I, Scheinberg IH. Prevention of Wilson's disease in asymptomatic patients. *N Engl J Med*. 1968;278:352–9.
  262. Paternostro R, Pfeifferberger J, Ferenci P, Stättermayer AF, Stauber RE, Wrba F, et al. Non-invasive diagnosis of cirrhosis and long-term disease monitoring by transient elastography in patients with Wilson disease. *Liver Int*. 2020;40:894–904.
  263. Schilsky ML, Scheinberg IH, Sternlieb I. Prognosis of Wilsonian chronic active hepatitis. *Gastroenterology*. 1991;100:762–.
  264. Scheinberg IH, Jaffe ME, Sternlieb I. The use of trientine in preventing the effects of interrupting penicillamine therapy in Wilson's disease. *N Engl J Med*. 1987;317:209–13.
  265. Walshe JM. Wilson's disease. New oral therapy. *Lancet*. 1956; 267:25–6.
  266. Scheinberg IH, Sternlieb I, Schilsky M, Stockert RJ. Penicillamine may detoxify copper in Wilson's disease. *Lancet*. 1987; 330:95.
  267. Perrett D. The metabolism and pharmacology of D-penicillamine in man. *J Rheumatol Suppl*. 1981;7:41–50.
  268. Wiesner RH, Dickson ER, Carlson GL, McPhaul LW, Go VL. The pharmacokinetics of D-penicillamine in man. *J Rheumatol Suppl*. 1981;7:51–.
  269. Bergstrom RF, Kay DR, Harkcom TM, Wagner JG. Penicillamine kinetics in normal subjects. *Clin Pharmacol Ther*. 1981; 30:404–13.
  270. Schuna A, Osman MA, Patel RB, Welling PG, Sundstrom WR. Influence of food on the bioavailability of penicillamine. *J Rheumatol*. 1983;10:95–7.
  271. Kukovetz WR, Beubler E, Kreuzig F, Moritz AJ, Nimberger G, Werner-Breitenecker L. Bioavailability and pharmacokinetics of D-penicillamine. *J Rheumatol*. 1983;10:90–4.
  272. Wei P, Sass-Kortsak A. Urinary excretion and renal clearance of D-penicillamine in humans and the dog. *Gastroenterology*. 1970;58:24.
  273. Falkmer S, Samuelson G, Sjölin S. Penicillamine-induced normalization of clinical signs, and liver morphology and histochemistry in a case of Wilson's disease. *Pediatrics*. 1970;45:260–8.
  274. Walshe JM. Copper chelation in patients with Wilson's disease. A comparison of penicillamine and triethylene tetramine dihydrochloride. *QJM*. 1973;42:441–52.
  275. Sass-Kortsak A. Wilson's disease. A treatable liver disease in children. *Pediatr Clin North Am*. 1975;22:963–84.
  276. Grand RJ, Vawter GF. Juvenile Wilson disease: histologic and functional studies during penicillamine therapy. *J Pediatr*. 1975; 87:1161–70.
  277. Sternlieb I. Copper and the liver. *Gastroenterology*. 1980;78: 1615–28.
  278. Członkowska A, Gajda J, Rodo M. Effects of long-term treatment in Wilson's disease with D-penicillamine and zinc sulphate. *J Neurol*. 1996;243:269–73.
  279. Brewer GJ, Terry CA, Aisen AM, Hill GM. Worsening of neurologic syndrome in patients with Wilson's disease with initial penicillamine therapy. *Arch Neurol*. 1987;44:490–3.
  280. Litwin T, Dzieżyc K, Karliński M, Chabik G, Czepiel W, Członkowska A. Early neurological worsening in patients with Wilson's disease. *J Neurol Sci*. 2015;355:162–7.
  281. Bécuwe C, Dalle S, Ronger-Savlé S, Skowron F, Balme B, Kanitakis J, et al. Elastosis perforans serpiginosa associated with pseudo-pseudoxanthoma elasticum during treatment of Wilson's disease with penicillamine. *Dermatology*. 2005;210:60–3.
  282. Deutscher J, Kiess W, Scheerschmidt G, Willgerodt H. Potential hepatotoxicity of penicillamine treatment in three patients with Wilson's disease. *J Pediatr Gastroenterol Nutr*. 1999;29:628.
  283. Shiono Y, Wakusawa S, Hayashi H, Takikawa T, Yano M, Okada T, et al. Iron accumulation in the liver of male patients with Wilson's disease. *Am J Gastroenterol*. 2001;96: 3147–51.
  284. Lu J, Poppitt SD, Othman AA, Sunderland T, Ruggiero K, Willett MS, et al. Pharmacokinetics, pharmacodynamics, and metabolism of triethylenetetramine in healthy human participants: an open-label trial. *J Clin Pharmacol*. 2010;50:647–58.
  285. Pfeifferberger J, Kruse C, Mutch P, Harker A, Weiss KH. The steady state pharmacokinetics of trientine in Wilson disease patients. *Eur J Clin Pharmacol*. 2018;74:731–6.
  286. Kodama H, Murata Y, Iitsuka T, Abe T. Metabolism of administered triethylene tetramine dihydrochloride in humans. *Life Sci*. 1997;61:899–907.
  287. Sarkar B, Sass-Kortsak A, Clarke R, Laurie SH, Wei P. A comparative study of in vitro and in vivo interaction of D-penicillamine and triethylene-tetramine with copper. *Proc R Soc Med*. 1977;70(Suppl 3):13–8.
  288. Borthwick TR, Benson GD, Schugar HJ. Copper chelating agents. A comparison of cupruric responses to various tetramines and D-penicillamine. *J Lab Clin Med*. 1980;95: 575–80.
  289. Walshe JM. The management of Wilson's disease with triethylene tetramine 2HC1 (Trient 2HC1). *Prog Clin Biol Res*. 1979;34:271–80.
  290. Saito H, Watanabe K, Sahara M, Mochizuki R, Edo K, Ohyama Y. Triethylene-tetramine (trien) therapy for Wilson's disease. *Tohoku J Exp Med*. 1991;164:29–35.
  291. Santos Silva EE, Sarles J, Buts JP, Sokal EM. Successful medical treatment of severely decompensated Wilson disease. *J Pediatr*. 1996;128:285–7.
  292. Taylor RM, Chen Y, Dhawan A, on behalf of the EuroWilson Consortium. Triethylene tetramine dihydrochloride (trientine) in children with Wilson disease: experience at King's College Hospital and review of the literature. *Eur J Pediatr*. 2009;168: 1061–8.
  293. Mayr T, Ferenci P, Weiler M, Fichtner A, Mehrabi A, Hoffmann GF, et al. Optimized trientine-dihydrochloride therapy in pediatric patients with Wilson disease: is weight-based dosing justified? *J Pediatr Gastroenterol Nutr*. 2021;72:115–22.
  294. Boga S, Jain D, Schilsky ML. Trientine induced colitis during therapy for Wilson disease: a case report and review of the literature. *BMC Pharmacol Toxicol*. 2015;16:30.
  295. Epstein O, Sherlock S. Triethylene tetramine dihydrochloride toxicity in primary biliary cirrhosis. *Gastroenterology*. 1980;78: 1442–5.
  296. Ala A, Aliu E, Schilsky ML. Prospective pilot study of a single daily dosage of trientine for the treatment of Wilson disease. *Dig Dis Sci*. 2015;60:1433–9.
  297. Pfeifferberger J, Lohse CM, Gotthardt D, Rupp C, Weiler M, Teufel U, et al. Long-term evaluation of urinary copper excretion and non-caeruloplasmin associated copper in Wilson disease patients under medical treatment. *J Inher Metab Dis*. 2019;42: 371–80.
  298. Hoogenraad TU, Koevoet R, de Ruyter Korver EG. Oral zinc sulphate as long-term treatment in Wilson's disease (hepatolenticular degeneration). *Eur Neurol*. 1979;18:205–11.

299. Hoogenraad TU, Van Hattum J, Van den Hamer CJ. Management of Wilson's disease with zinc sulphate. Experience in a series of 27 patients. *J Neurol Sci.* 1987;77:137–46.
300. Brewer GJ, Yuzbasiyan-Gurkan V, Young AB. Treatment of Wilson's disease. *Semin Neurol.* 1987;7:209–.
301. Brewer GJ, Hill GM, Prasad AS, Cossack ZT, Rabbani P. Oral zinc therapy for Wilson's disease. *Ann Intern Med.* 1983;99:314–9.
302. Schilsky M, Blank RR, Czaja MJ, Zern MA, Scheinberg IH, Stockert RJ, et al. Hepatocellular copper toxicity and its attenuation by zinc. *J Clin Invest.* 1989;84:1562–8.
303. Wooton-Kee CR, Jain AK, Wagner M, Grusak MA, Finegold MJ, Lutsenko S, et al. Elevated copper impairs hepatic nuclear receptor function in Wilson's disease. *J Clin Invest.* 2015;125:3449–60.
304. Camarata MA, Ala A, Schilsky ML. Zinc maintenance therapy for Wilson disease: a comparison between zinc acetate and alternative zinc preparations. *Hepatol Commun.* 2019;3:1151–8.
305. Wiernicka A, Jańczyk W, Dądalski M, Avsar Y, Schmidt H, Socha P. Gastrointestinal side effects in children with Wilson's disease treated with zinc sulphate. *World J Gastroenterol.* 2013;19:4356–62.
306. Santiago R, Gottrand F, Debray D, Bridoux L, Lachaux A, Morali A, et al. Zinc therapy for Wilson disease in children in French pediatric centers. *J Pediatr Gastroenterol Nutr.* 2015;61:613–8.
307. Brewer GJ, Hill G, Prasad A, Dick R. The treatment of Wilson's disease with zinc. IV. Efficacy monitoring using urine and plasma copper. *Proc Soc Exp Biol Med.* 1987;184:446–55.
308. Lang CJ, Rabas-Kolominsky P, Engelhardt A, Kobras G, König HJ. Fatal deterioration of Wilson's disease after institution of oral zinc therapy. *Arch Neurol.* 1993;50:1007–8.
309. Walshe JM, Munro NA. Zinc-induced deterioration in Wilson's disease aborted by treatment with penicillamine, dimercaprol, and a novel zero copper diet. *Arch Neurol.* 1995;52:10.
310. Weiss KH, Gotthardt DN, Klemm D, Merle U, Ferenci-Foerster D, Schaefer M, et al. Zinc monotherapy is not as effective as chelating agents in treatment of Wilson disease. *Gastroenterology.* 2011;140:1189–98.
311. Członkowska A, Litwin T, Karliński M, Dziezyc K, Chabik G, Czerska M. D-penicillamine versus zinc sulfate as first-line therapy for Wilson's disease. *Eur J Neurol.* 2014;21:599–606.
312. Brewer GJ, Dick RD, Johnson VD, Brunberg JA, Kluin KJ, Fink JK. Treatment of Wilson's disease with zinc: XV long-term follow-up studies. *J Lab Clin Med.* 1998;132:264–78.
313. Linn FH, Houwen RH, van Hattum J, van der Kleij S, van Erpecum KJ. Long-term exclusive zinc monotherapy in symptomatic Wilson disease: experience in 17 patients. *Hepatology.* 2009;50:1442–52.
314. Marcellini M, Di Ciommo V, Callea F, Devito R, Comparcola D, Sartorelli MR, et al. Treatment of Wilson's disease with zinc from the time of diagnosis in pediatric patients: a single-hospital, 10-year follow-up study. *J Lab Clin Med.* 2005;145:139–43.
315. Mizuochi T, Kimura A, Shimizu N, Nishiura H, Matsushita M, Yoshino M. Zinc monotherapy from time of diagnosis for young pediatric patients with presymptomatic Wilson disease. *J Pediatr Gastroenterol Nutr.* 2011;53:365–7.
316. Ranucci G, Di Dato F, Spagnuolo MI, Vajro P, Iorio R. Zinc monotherapy is effective in Wilson's disease patients with mild liver disease diagnosed in childhood: a retrospective study. *Orphanet J Rare Dis.* 2014;9:41.
317. Lee VD, Northup PG, Berg CL. Resolution of decompensated cirrhosis from Wilson's disease with zinc monotherapy: a potential therapeutic option? *Clin Gastroenterol Hepatol.* 2006;4:1069–71.
318. Brewer GJ, Dick RD, Johnson VD, Fink JK, Kluin KJ, Daniels S. Treatment of Wilson's disease with zinc XVI: treatment during the pediatric years. *J Lab Clin Med.* 2001;137:191–8.
319. Van Caillie-Bertrand M, Degenhart HJ, Visser HK, Sinaasappel M, Bouquet J. Oral zinc sulphate for Wilson's disease. *Arch Dis Child.* 1985;60:656–9.
320. Pécoud A, Donzel F, Schelling JL. The effect of foodstuffs on the absorption of zinc sulfate. *Clin Pharmacol Ther.* 1975;17:469–74.
321. Dziezyc K, Litwin T, Sobańska A, Członkowska A. Symptomatic copper deficiency in three Wilson's disease patients treated with zinc sulphate. *Neurol Neurochir Pol.* 2014;48:214–8.
322. Plitz T, Boyling L. Metabolic disposition of WTX101 (bis-choline tetrathiomolybdate) in a rat model of Wilson disease. *Xenobiotica.* 2019;49:332–8.
323. Ogra Y, Suzuki KT. Targeting of tetrathiomolybdate on the copper accumulating in the liver of LEC rats. *J Inorg Biochem.* 1998;70:49–55.
324. Weiss KH, Askari FK, Członkowska A, Ferenci P, Bronstein JM, Bega D, et al. Bis-choline tetrathiomolybdate in patients with Wilson's disease: an open-label, multicentre, phase 2 study. *Lancet Gastroenterol Hepatol.* 2017;2:869–76.
325. von Herbay A, de Groot H, Hegi U, Stremmel W, Strohmeyer G, Sies H. Low vitamin E content in plasma of patients with alcoholic liver disease, hemochromatosis and Wilson's disease. *J Hepatol.* 1994;20:41–6.
326. Sokol RJ, Twedt D, McKim JM Jr, Devereaux MW, Karrer FM, Kam I, et al. Oxidant injury to hepatic mitochondria in patients with Wilson's disease and Bedlington terriers with copper toxicosis. *Gastroenterology.* 1994;107:1788–98.
327. Ogihara H, Ogihara T, Miki M, Yasuda H, Mino M. Plasma copper and antioxidant status in Wilson's disease. *Pediatr Res.* 1995;37:219–6.
328. Sinha S, Christopher R, Arunodaya GR, Prashanth LK, Gopinath G, Swamy HS, et al. Is low serum tocopherol in Wilson's disease a significant symptom? *J Neurol Sci.* 2005;228:121–3.
329. Bruha R, Vitek L, Marecek Z, Pospisilova L, Nevsimilova S, Martasek P, et al. Decreased serum antioxidant capacity in patients with Wilson disease is associated with neurological symptoms. *J Inher Metab Dis.* 2012;35:541–8.
330. Kalita J, Kumar V, Misra UK, Ranjan A, Khan H, Konwar R. A study of oxidative stress, cytokines and glutamate in Wilson disease and their asymptomatic siblings. *J Neuroimmunol.* 2014;274:141–8.
331. Nagasaka H, Inoue I, Inui A, Komatsu H, Sogo T, Murayama K, et al. Relationship between oxidative stress and antioxidant systems in the liver of patients with Wilson disease: hepatic manifestation in Wilson disease as a consequence of augmented oxidative stress. *Pediatr Res.* 2006;60:472–7.
332. Kalita J, Kumar V, Misra UK, Parashar V, Ranjan A. Adjunctive antioxidant therapy in neurologic Wilson's disease improves the outcomes. *J Mol Neurosci.* 2020;70:378–85.
333. Walshe JM. Diagnosis and treatment of presymptomatic Wilson's disease. *Lancet.* 1988;332:435–7.
334. Brewer GJ, Yuzbasiyan-Gurkan V, Lee DY, Appelman H. Treatment of Wilson's disease with zinc. VI. Initial treatment studies. *J Lab Clin Med.* 1989;114:633–8.
335. Arnon R, Calderon JF, Schilsky M, Emre S, Shneider BL. Wilson disease in children: serum aminotransferases and urinary copper on triethylene tetramine dihydrochloride (trientine) treatment. *J Pediatr Gastroenterol Nutr.* 2007;44:596–602.
336. Institute of Medicine (US) Panel on Micronutrients. Copper. In: Dietary reference intakes for vitamin A, vitamin K, arsenic, boron, chromium, copper, iodine, iron, manganese, molybdenum, nickel, silicon, vanadium, and zinc. Washington, DC: National Academies Press; 2001. p. 224–52. <https://www.ncbi.nlm.nih.gov/books/NBK222312/>

337. Sturm E, Piersma FE, Tanner MS, Socha P, Roberts EA, Shneider BL. Controversies and variation in diagnosing and treating children with Wilson disease: results of an international survey. *J Pediatr Gastroenterol Nutr*. 2016;63:82–7.
338. Russell K, Gillanders LK, Orr DW, Plank LD. Dietary copper restriction in Wilson's disease. *Eur J Clin Nutr*. 2018;72:326–1.
339. Brewer GJ, Yuzbasiyan-Gurkan VI, Dick R, Wang YU, Johnson V. Does a vegetarian diet control Wilson's disease? *J Am Coll Nutr*. 1993;12:527–30.
340. Kawai K, Atarashi Y, Takahara T, Kudo H, Tajiri K, Tokimitsu Y, et al. Dietary supplement implicated in fulminant hepatic failure in a well-controlled Wilson disease patient. *Clin J Gastroenterol*. 2009;2:119–24.
341. Khaghani S, Ezzatpanah H, Mazhari N, Givianrad MH, Mirmiranpour H, Sadrabadi FS. Zinc and copper concentrations in human milk and infant formulas. *Iran J Pediatr*. 2010;20:53–7.
342. World Health Organization. Copper in drinking-water – background document for development of WHO Guidelines for Drinking-water Quality. 2004. <https://www.who.int/teams/environment-climate-change-and-health/water-sanitation-and-health/chemical-hazards-in-drinking-water/copper>. Accessed August 18, 2022.
343. Chanpong A, Dhawan A. Long-term urinary copper excretion on chelation therapy in children with Wilson disease. *J Pediatr Gastroenterol Nutr*. 2021;72:210–5.
344. Czlonkowska A, Tarnacka B, Litwin T, Gajda J, Rodo M. Wilson's disease—cause of mortality in 164 patients during 1992–2003 observation period. *J Neurol*. 2005;252:698–703.
345. Bruha R, Marecek Z, Pospisilova L, Nevsimalova S, Vitek L, Martasek P, et al. Long-term follow-up of Wilson disease: natural history, treatment, mutations analysis and phenotypic correlation. *Liver Int*. 2011;31:83–91.
346. Bem RS, Muzzillo DA, Deguti MM, Barbosa ER, Werneck LC, Teive HAG. Wilson's disease in southern Brazil: a 40-year follow-up study. *Clinics (Sao Paulo)*. 2011;66:411–6.
347. Beinhardt S, Leiss W, Stättermayer AF, Graziadei I, Zoller H, Stauber R, et al. Long-term outcomes of patients with Wilson disease in a large Austrian cohort. *Clin Gastroenterol Hepatol*. 2014;12:683–9.
348. Cheung KS, Seto WK, Fung J, Mak LY, Lai CL, Yuen MF. Epidemiology and natural history of Wilson's disease in the Chinese: a territory-based study in Hong Kong between 2000 and 2016. *World J Gastroenterol*. 2017;23:7716–26.
349. Dubbioso R, Ranucci G, Esposito M, Di Dato F, Topa A, Quarantelli M, et al. Subclinical neurological involvement does not develop if Wilson's disease is treated early. *Parkinsonism Relat Disord*. 2016;24:15–9.
350. Osterberg L, Blaschke T. Adherence to medication. *N Engl J Med*. 2005;353:487–97.
351. Dziezyc K, Karliński M, Litwin T, Czlonkowska A. Compliant treatment with anti-copper agents prevents clinically overt Wilson's disease in pre-symptomatic patients. *Eur J Neurol*. 2014;21:332–7.
352. Jacquelet E, Beretti J, De-Tassigny A, Girardot-Tinant N, Wenisch E, Lachaux A, et al. Compliance with treatment in Wilson's disease: on the interest of a multidisciplinary closer follow-up. *Rev Med Interne*. 2018;39:155–60.
353. Shemesh E, Annunziato RA, Arnon R, Miloh T, Kerker N. Adherence to medical recommendations and transition to adult services in pediatric transplant recipients. *Curr Opin Organ Transplant*. 2010;15:288–92.
354. Walshe JM, Dixon AK. Dangers of non-compliance in Wilson's disease. *Lancet*. 1986;327:845–7.
355. Askari FK, Greenson J, Dick RD, Johnson VD, Brewer GJ. Treatment of Wilson's disease with zinc. XVIII. Initial treatment of the hepatic decompensation presentation with trientine and zinc. *J Lab Clin Med*. 2003;142:385–90.
356. Rakela J, Kurtz SB, McCarthy JT, Ludwig J, Ascher NL, Bloomer JR, et al. Fulminant Wilson's disease treated with postdilution hemofiltration and orthotopic liver transplantation. *Gastroenterology*. 1986;90:2004–7.
357. Rakela J, Kurtz SB, McCarthy JT, Krom RA, Baldus WP, McGill DB, et al. Postdilution hemofiltration in the management of acute hepatic failure: a pilot study. *Mayo Clin Proc*. 1988;63:113–8.
358. Sarles J, Lefevre P, Picon G. Plasma exchange for fulminant Wilson disease. *Eur J Pediatr*. 1992;151:310.
359. Kiss JE, Berman D, Van Thiel D. Effective removal of copper by plasma exchange in fulminant Wilson's disease. *Transfusion*. 1998;38:327–1.
360. Kreymann B, Seige M, Schweigart U, Kopp KF, Classen M. Albumin dialysis: effective removal of copper in a patient with fulminant Wilson disease and successful bridging to liver transplantation: a new possibility for the elimination of protein-bound toxins. *J Hepatol*. 1999;31:1080–5.
361. Stange J, Mitzner SR, Risler T, Erley CM, Lauchart W, Goehl H, et al. Molecular adsorbent recycling system (MARS): clinical results of a new membrane-based blood purification system for bioartificial liver support. *Artif Organs*. 1999;23:319–0.
362. Sen S, Felldin M, Steiner C, Larsson B, Gillett GT, Olausson M, et al. Albumin dialysis and molecular adsorbents recirculating system (MARS) for acute Wilson's disease. *Liver Transpl*. 2002;8:962–7.
363. Auth MK, Kim HS, Beste M, Bonzel KE, Baumann U, Ballauff A, et al. Removal of metabolites, cytokines and hepatic growth factors by extracorporeal liver support in children. *J Pediatr Gastroenterol Nutr*. 2005;40:54–9.
364. Jhang JS, Schilsky ML, Lefkowitz JH, Schwartz J. Therapeutic plasmapheresis as a bridge to liver transplantation in fulminant Wilson disease. *J Clin Apher*. 2007;22:10–4.
365. Collins KL, Roberts EA, Adeli K, Bohn D, Harvey EA. Single pass albumin dialysis (SPAD) in fulminant Wilsonian liver failure: a case report. *Pediatr Nephrol*. 2008;23:1013–6.
366. Rustom N, Bost M, Cour-Andlauer F, Lachaux A, Brunet AS, Boillot O, et al. Effect of molecular adsorbents recirculating system treatment in children with acute liver failure caused by Wilson disease. *J Pediatr Gastroenterol Nutr*. 2014;58:160–4.
367. Pham HP, Schwartz J, Cooling L, Hofmann JC, Kim HC, Morgan S, et al. Report of the ASFA apheresis registry study on Wilson's disease. *J Clin Apher*. 2016;31:11–5.
368. Bakhsha S, Teoh CW, Harvey EA, Noone DG. Single pass albumin dialysis and plasma exchange for copper toxicity in acute Wilson disease. *Case Rep Nephrol Dial*. 2019;9:55–63.
369. Sukezaki A, Chu PS, Shinoda M, Hibi T, Taniki N, Yoshida A, et al. Late-onset acute liver failure due to Wilson's disease managed by plasmapheresis and hemodiafiltration successfully serving as a bridge for deceased donor liver transplantation: a case report and literature review. *Clin J Gastroenterol*. 2020;13:1239–46.
370. Oosthuizen NM. Undetectable serum alkaline phosphatase activity in a patient with fulminant hepatic failure and hemolytic anemia. *Clin Chem*. 2011;57:382–5.
371. Arnon R, Annunziato R, Schilsky M, Miloh T, Willis A, Sturdevant M, et al. Liver transplantation for children with Wilson disease: comparison of outcomes between children and adults. *Clin Transplant*. 2011;25:E52–60.
372. Heimbach JK, Kulik LM, Finn RS, Sirlin CB, Abecassis MM, Roberts LR, et al. AASLD guidelines for the treatment of hepatocellular carcinoma. *Hepatology*. 2018;67:358–80.
373. Guarino M, Stracciari A, D'Alessandro R, Pazzaglia P. No neurological improvement after liver transplantation for Wilson's disease. *Acta Neurol Scand*. 1995;92:405–8.
374. Kassam N, Witt N, Kneteman N, Bain VG. Liver transplantation for neuropsychiatric Wilson disease. *Can J Gastroenterol*. 1998;12:65–8.



375. Eghtesad B, Nezakatgoo N, Geraci LC, Jabbour N, Irish WD, Marsh W, et al. Liver transplantation for Wilson's disease: a single-center experience. *Liver Transpl Surg.* 1999;5:467–74.
376. Brewer GJ, Askari F. Transplant livers in Wilson's disease for hepatic, not neurologic, indications. *Liver Transpl.* 2000;6:662–4.
377. Senzolo M, Loreno M, Fagioli S, Zanusi G, Canova D, Masier A, et al. Different neurological outcome of liver transplantation for Wilson's disease in two homozygotic twins. *Clin Neurol Neurosurg.* 2007;109:71–5.
378. Medici V, Mirante VG, Fassati LR, Pompili M, Forti D, Del Gaudio M, et al. Liver transplantation for Wilson's disease: the burden of neurological and psychiatric disorders. *Liver Transpl.* 2005;11:1056–63.
379. Schumacher G, Platz KP, Mueller AR, Neuhaus R, Steinmüller T, Bechstein WO, et al. Liver transplantation: treatment of choice for hepatic and neurological manifestation of Wilson's disease. *Clin Transplant.* 1997;11:217–4.
380. Weiss KH, Schäfer M, Gotthardt DN, Angerer A, Mogler C, Schirmacher P, et al. Outcome and development of symptoms after orthotopic liver transplantation for Wilson disease. *Clin Transplant.* 2013;27:914–22.
381. Bax RT, Hässler A, Luck W, Heftner H, Krägeloh-Mann I, Neuhaus P, et al. Cerebral manifestation of Wilson's disease successfully treated with liver transplantation. *Neurology.* 1998;51:863–5.
382. Lui CC, Chen CL, Cheng YF, Lee TY. Recovery of neurological deficits in a case of Wilson's disease after liver transplantation. *Transplant Proc.* 1998;30:3324–5.
383. Stracciari A, Tempestini A, Borghi A, Guarino M. Effect of liver transplantation on neurological manifestations in Wilson disease. *Arch Neurol.* 2000;57:384–6.
384. Wu JC, Huang CC, Jeng LB, Chu NS. Correlation of neurological manifestations and MR images in a patient with Wilson's disease after liver transplantation. *Acta Neurol Scand.* 2000;102:135–9.
385. Poujois A, Sobesky R, Meissner WG, Brunet AS, Brousseau E, Laurencin C, et al. Liver transplantation as a rescue therapy for severe neurologic forms of Wilson disease. *Neurology.* 2020;94:e2189–202.
386. Asonuma K, Inomata Y, Kasahara M, Uemoto S, Egawa H, Fujita S, et al. Living related liver transplantation from heterozygote genetic carriers to children with Wilson's disease. *Pediatr Transplant.* 1999;3:201–5.
387. Komatsu H, Fujisawa T, Inui A, Sogo T, Sekine I, Kodama H, et al. Hepatic copper concentration in children undergoing living related liver transplantation due to Wilsonian fulminant hepatic failure. *Clin Transplant.* 2002;16:227–32.
388. Wang XH, Cheng F, Zhang F, Li XC, Kong LB, Li GQ, et al. Living-related liver transplantation for Wilson's disease. *Transpl Int.* 2005;18:651–.
389. Tamura S, Sugawara Y, Kishi Y, Akamatsu N, Kaneko J, Makuuchi M. Living-related liver transplantation for Wilson's disease. *Clin Transplant.* 2005;19:483–6.
390. Guillaud O, Dumortier J, Sobesky R, Debray D, Wolf P, Vanlemmens C, et al. Long term results of liver transplantation for Wilson's disease: experience in France. *J Hepatol.* 2014;60:579–89.
391. van Meer S, de Man RA, van den Berg AP, Houwen RHJ, Linn FHH, van Oijen MGH, et al. No increased risk of hepatocellular carcinoma in cirrhosis due to Wilson disease during long-term follow-up. *J Gastroenterol Hepatol.* 2015;30:535–9.
392. Al Fadda M, Al Quaiz M, Al Ashgar H, Al Kahtani K, Helmy A, Al Benmoussa A, et al. Wilson disease in 71 patients followed for over two decades in a tertiary center in Saudi Arabia: a retrospective review. *Ann Saudi Med.* 2012;32:623–9.
393. Walshe JM, Waldenström E, Sams V, Nordlinder H, Westermarck K. Abdominal malignancies in patients with Wilson's disease. *QJM.* 2003;96:657–2.
394. Iwadate H, Ohira H, Suzuki T, Abe K, Yokokawa J, Takiguchi J, et al. Hepatocellular carcinoma associated with Wilson's disease. *Intern Med.* 2004;43:1042–5.
395. Kumagi T, Horiike N, Michitaka K, Hasebe A, Kawai K, Tokumoto Y, et al. Recent clinical features of Wilson's disease with hepatic presentation. *J Gastroenterol.* 2004;39:1165–9.
396. Kumagi T, Horiike N, Abe M, Kurose K, Iuchi H, Masumoto T, et al. Small hepatocellular carcinoma associated with Wilson's disease. *Intern Med.* 2005;44:439–.
397. Xu R, Bu-Ghanim M, Fiel MI, Schiano T, Cohen E, Thung SN. Hepatocellular carcinoma associated with an atypical presentation of Wilson's disease. *Semin Liver Dis.* 2007;27:122–7.
398. Pfeiffenberger J, Mogler C, Gotthardt DN, Schulze-Bergkamen H, Litwin T, Reuner U, et al. Hepatobiliary malignancies in Wilson disease. *Liver Int.* 2015;35:1615–22.
399. Savas N, Canan O, Ozcay F, Bilezikci B, Karakayali H, Yilmaz U, et al. Hepatocellular carcinoma in Wilson's disease: a rare association in childhood. *Pediatr Transplant.* 2006;10:639–43.
400. Rosencrantz RA, LeCompte L, Yusuf Y. Beneath the copper-pediatric Wilson's disease cirrhosis and hepatocellular carcinoma: a case report with literature review. *Semin Liver Dis.* 2015;35:434–8.
401. Iorio GG, Conforti A, Vallone R, Carbone L, Matarazzo M, De Rosa A, et al. Reproductive function of long-term treated patients with hepatic onset of Wilson's disease: a prospective study. *Reprod Biomed Online.* 2021;42:835–41.
402. Schagen van Leeuwen JH, Christiaens GC, Hoogenraad TU. Recurrent abortion and the diagnosis of Wilson disease. *Obstet Gynecol.* 1991;78:547–9.
403. Pfeiffenberger J, Beinhardt S, Gotthardt DN, Haag N, Freissmuth C, Reuner U, et al. Pregnancy in Wilson's disease: management and outcome. *Hepatology.* 2018;67:1261–9.
404. Flemming JA, Mullin M, Lu J, Sarkar MA, Djerboua M, Velez MP, et al. Outcomes of pregnant women with cirrhosis and their infants in a population-based study. *Gastroenterology.* 2020;159:1752–62.
405. Torbenson V, Rose C. Wilson disease: implications for pregnancy. In: Kerker N, Roberts EA, editors. *Clinical and translational perspectives on Wilson disease.* London: Academic Press; 2018. p. 409–17.
406. Shimono N, Ishibashi H, Ikematsu H, Kudo J, Shirahama M, Inaba S, et al. Fulminant hepatic failure during perinatal period in a pregnant woman with Wilson's disease. *Gastroenterol Jpn.* 1991;26:69–73.
407. Yu XE, Pan M, Han YZ, Yang RM, Wang J, Gao S. The study of Wilson disease in pregnancy management. *BMC Pregnancy Childbirth.* 2019;19:522.
408. Sternlieb I. Wilson's disease and pregnancy. *Hepatology.* 2000;31:531–2.
409. Brewer GJ, Johnson VD, Dick RD, Hedera P, Fink JK, Klun KJ. Treatment of Wilson's disease with zinc. XVII: treatment during pregnancy. *Hepatology.* 2000;31:364–70.
410. Dathe K, Beck E, Schaefer C. Pregnancy outcome after chelation therapy in Wilson disease. Evaluation of the German Embryotox Database. *Reprod Toxicol.* 2016;65:39–45.
411. Hanukoglu A, Curiel B, Berkowitz D, Levine A, Sack J, Lorberboym M. Hypothyroidism and dysmorphogenesis induced by D-penicillamine in children with Wilson's disease and healthy infants born to a mother with Wilson's disease. *J Pediatr.* 2008;153:864–6.
412. Pinter R, Hogge WA, McPherson E. Infant with severe penicillamine embryopathy born to a woman with Wilson disease. *Am J Med Genet A.* 2004;128:294–8.
413. Michalczyk A, Bastow E, Greenough M, Camakaris J, Free-stone D, Taylor P, et al. ATP7B expression in human breast epithelial cells is mediated by lactational hormones. *J Histochem Cytochem.* 2008;56:389–99.

414. Ackland ML, Michalczyk AA. Zinc and infant nutrition. *Arch Biochem Biophys*. 2016;611:51–7.
415. Krebs NF, Reidinger CJ, Hartley S, Robertson AD, Hambidge KM. Zinc supplementation during lactation: effects on maternal status and milk zinc concentrations. *Am J Clin Nutr*. 1995;61:1030–6.
416. Kannan S, Dick RB, Johnson V, Brewer GJ. Effect of zinc treatment for Wilson's disease on zinc concentration in breast milk (abstract). *J Trace Elem Exp Med*. 2001;14:283.
417. Kodama H, Anan Y, Izumi Y, Sato Y, Ogra Y. Copper and zinc concentrations in the breast milk of mothers undergoing treatment for Wilson's disease: a prospective study. *BMJ Paediatr Open*. 2021;5:e000948.
418. Weiss KH, Thurik F, Gotthardt DN, Schäfer M, Teufel U, Wiegand F, et al. Efficacy and safety of oral chelators in treatment of patients with Wilson disease. *Clin Gastroenterol Hepatol*. 2013;11:1028–35.
419. Brewer GJ. Penicillamine should not be used as initial therapy in Wilson's disease. *Mov Disord*. 1999;14:551–4.
420. Brewer GJ, Askari F, Dick RB, Sitterly J, Fink JK, Carlson M, et al. Treatment of Wilson's disease with tetrathiomolybdate: V. Control of free copper by tetrathiomolybdate and a comparison with trientine. *Transl Res*. 2009;154:70–.
421. Hefter H, Samadzadeh S. Effective treatment of neurological symptoms with normal doses of Botulinum neurotoxin in Wilson's disease: six cases and literature review. *Toxins (Basel)*. 2021;13:241.
422. Hedera P. Treatment of Wilson's disease motor complications with deep brain stimulation. *Ann N Y Acad Sci*. 2014;1315:16–23.
423. Srinivas K, Sinha S, Taly AB, Prashanth LK, Arunodaya GR, Janardhana Reddy YC, et al. Dominant psychiatric manifestations in Wilson's disease: a diagnostic and therapeutic challenge! *J Neurol Sci*. 2008;266:104–8.
424. Bachmann H, Lössner J, Kühn HJ, Biesold D, Siegemund R, Kunath B, et al. Long-term care and management of Wilson's disease in the GDR. *Eur Neurol*. 1989;29:301–5.
425. Modai I, Karp L, Liberman UA, Munitz HA. Penicillamine therapy for schizophreniform psychosis in Wilson's disease. *J Nerv Ment Dis*. 1985;173:698–701.
426. Zimbrea P, Seniów J. Cognitive and psychiatric symptoms in Wilson disease. *Handb Clin Neurol*. 2017;142:121–40.
427. Krim E, Barroso B. Psychiatric disorders treated with clozapine in a patient with Wilson's disease. *Presse Med*. 2001;30:738.
428. Kulaksizoglu IB, Polat A. Quetiapine for mania with Wilson's disease. *Psychosomatics*. 2003;44:438–9.
429. Kontaxakis V, Stefanis C, Markidis M, Tserpe V. Neuroleptic malignant syndrome in a patient with Wilson's disease. *J Neurol Neurosurg Psychiatry*. 1988;51:1001–2.
430. Zimbrea PC, Schilsky ML. The spectrum of psychiatric symptoms in Wilson's disease: treatment and prognostic considerations. *Am J Psychiatry*. 2015;172:1068–72.
431. Loganathan S, Nayak R, Sinha S, Taly AB, Math S, Varghese M. Treating mania in Wilson's disease with lithium. *J Neuropsychiatry Clin Neurosci*. 2008;20:487–9.
432. Vaishnav P, Gandhi HA. Electro convulsive therapy in psychiatric manifestations in Wilson's disease. *Indian J Psychol Med*. 2013;35:206–8.
433. Stenson PD, Mort M, Ball EV, Shaw K, Phillips A, Cooper DN. The Human Gene Mutation Database: building a comprehensive mutation repository for clinical and molecular genetics, diagnostic testing and personalized genomic medicine. *Hum Genet*. 2014;133:1–9.
434. Kumar M, Gaharwar U, Paul S, Poojary M, Pandhare K, Scaria V, et al. WilsonGen a comprehensive clinically annotated genomic variant resource for Wilson's Disease. *Sci Rep*. 2020;10:9037.
435. Kenney SM, Cox DW. Sequence variation database for the Wilson disease copper transporter, ATP7B. *Hum Mutat*. 2007;28:1171–7.
436. Roberts EA. Update on the diagnosis and management of Wilson disease. *Curr Gastroenterol Rep*. 2018;20:56.
437. Petrasek J, Milan J, Sperl J, Kozak L, Taimr P, Spicak J, et al. Revised King's College score for liver transplantation in adult patients with Wilson disease. *Liver Transpl*. 2007;13:55–61.
438. Sutcliffe RP, Maguire DD, Muiesan P, Dhawan A, Mieli-Vergani G, O'Grady JG, et al. Liver transplantation for Wilson's disease: long-term results and quality-of-life assessment. *Transplantation*. 2003;75:1003–6.
439. Sevmis S, Karakayali H, Aliosmanoglu I, Yilmaz U, Ozcay F, Torgay A, et al. Liver transplantation for Wilson's disease. *Transplant Proc*. 2008;40:228–30.
440. Cheng F, Li GQ, Zhang F, Li XC, Sun BC, Kong LB, et al. Outcomes of living-related liver transplantation for Wilson's disease: a single-center experience in China. *Transplantation*. 2009;87:751–.
441. Yoshitoshi EY, Takada Y, Oike F, Sakamoto S, Ogawa K, Kanazawa H, et al. Long-term outcomes for 32 cases of Wilson's disease after living-donor liver transplantation. *Transplantation*. 2009;87:261–7.
442. Ferrarese A, Morelli MC, Carrai P, Milana M, Angelico M, Perricone G, et al. Outcomes of liver transplant for adults with Wilson's disease. *Liver Transpl*. 2020;26:507–16.

**How to cite this article:** Schilsky ML, Roberts EA, Bronstein JM, Dhawan A, Hamilton JP, Rivard AM, et al. A multidisciplinary approach to the diagnosis and management of Wilson disease: 2022 practice guidance on Wilson disease from the American Association for the Study of Liver Diseases. *Hepatology*. 2023;00:1–49.  
<https://doi.org/10.1002/hep.32805>